


# ANATOMICAL FIGURING

Forensic Body Chart Resource



David Ranson

Victorian Institute of Forensic Medicine



**Case details:**

Case No. / UR No. .... Place of Examination .....  
Subjects Name .....  
Address ..... Address .....  
Age ..... D.O.B. / / M / F ..... Tel ..... Fax .....

**Consent:** Obtained from .....

Time called ..... hrs Time of arrival ..... hrs Time of departing ..... hrs  
(original callout) / / at scene / / from scene / /  
Time of commencement ..... hrs Time of completion ..... hrs Time of completion ..... hrs  
of examination / / of examination / / of notes / /

**Observers:**

Name	Status	Name	Status
.....	.....	.....	.....
.....	.....	.....	.....
.....	.....	.....	.....
.....	.....	.....	.....

**Circumstances / History:**

(a) From patient .....  
.....  
.....  
.....  
.....

**Clothing:**

.....  
.....  
.....  
.....  
.....

(b) From others (police, ambulance, family, friends, others)

Name of Informant .....  
.....  
.....  
.....  
.....

**Jewellery:**

.....  
.....  
.....  
.....  
.....

**Specimens:**

.....  
.....  
.....  
.....

**Specimens handed to:**

Recipient name .....  
Status .....  
Recipient signature .....  
Time ..... hrs Date / /

# Legend

(i) Whole body — front



(ii) Whole body — back



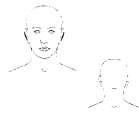
(iii) Whole body — side (R)



(iv) Whole body — side (L)



(v) Head — front and back



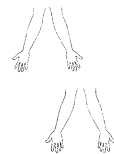(vi) Head — side (L & R)



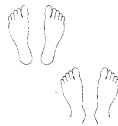(vii) Hands — back and palm (R & L)



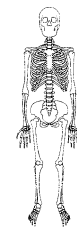
(viii) Forearms — (R & L)



(ix) Feet — soles and dorsum



(x) Whole body skeleton



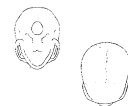(xi) Skull — front and back



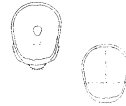
(xii) Skull — side (L & R)



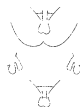(xiii) Skull — base and top



(xiv) Skull — inside



(xv) Genitalia — male



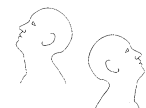(xvi) Genitalia — female



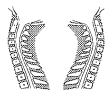(xvii) Extended neck — front and larynx



(xviii) Extended neck — side (L & R)



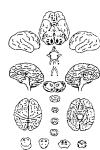(xix) Neck — section (R & L)



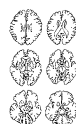(xx) Spine — three sections



(xxi) Brain — surfaces



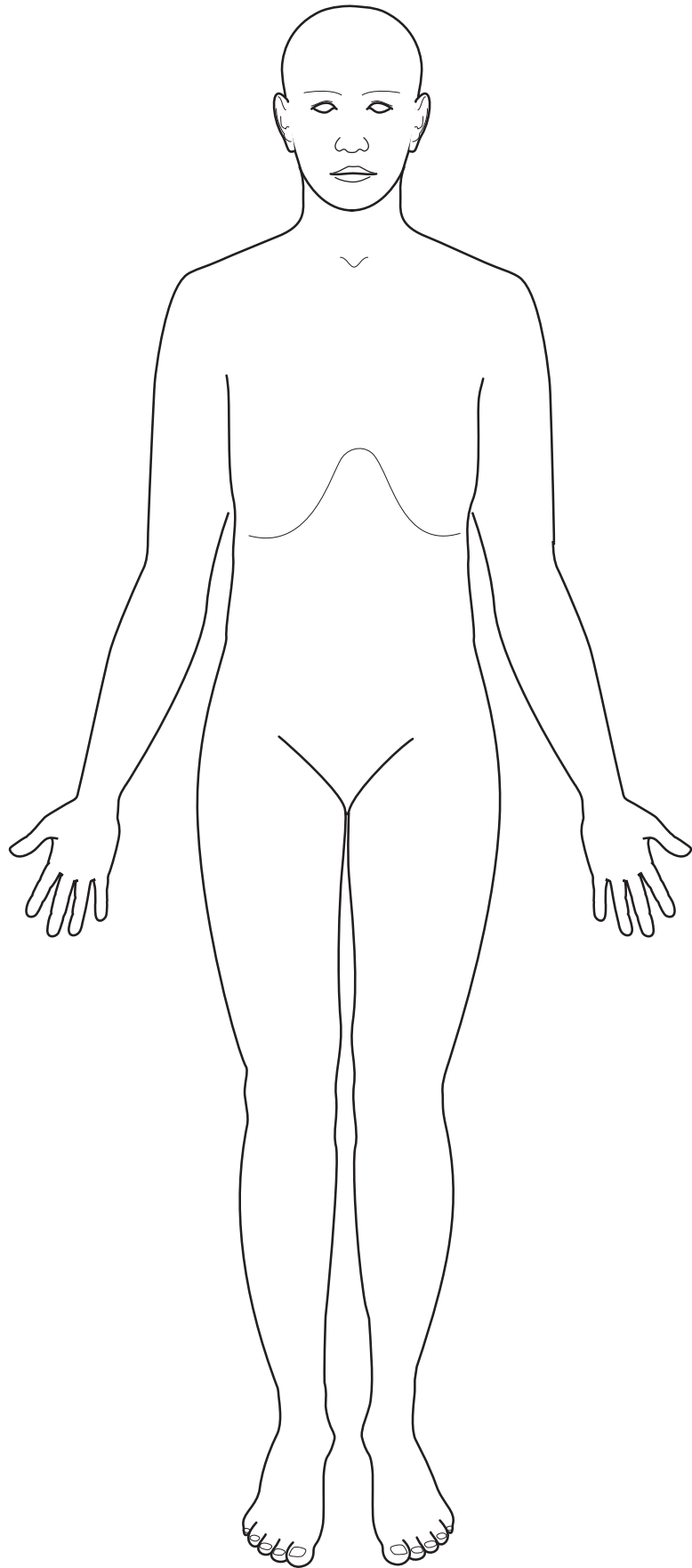
(xxii) Brain — slices



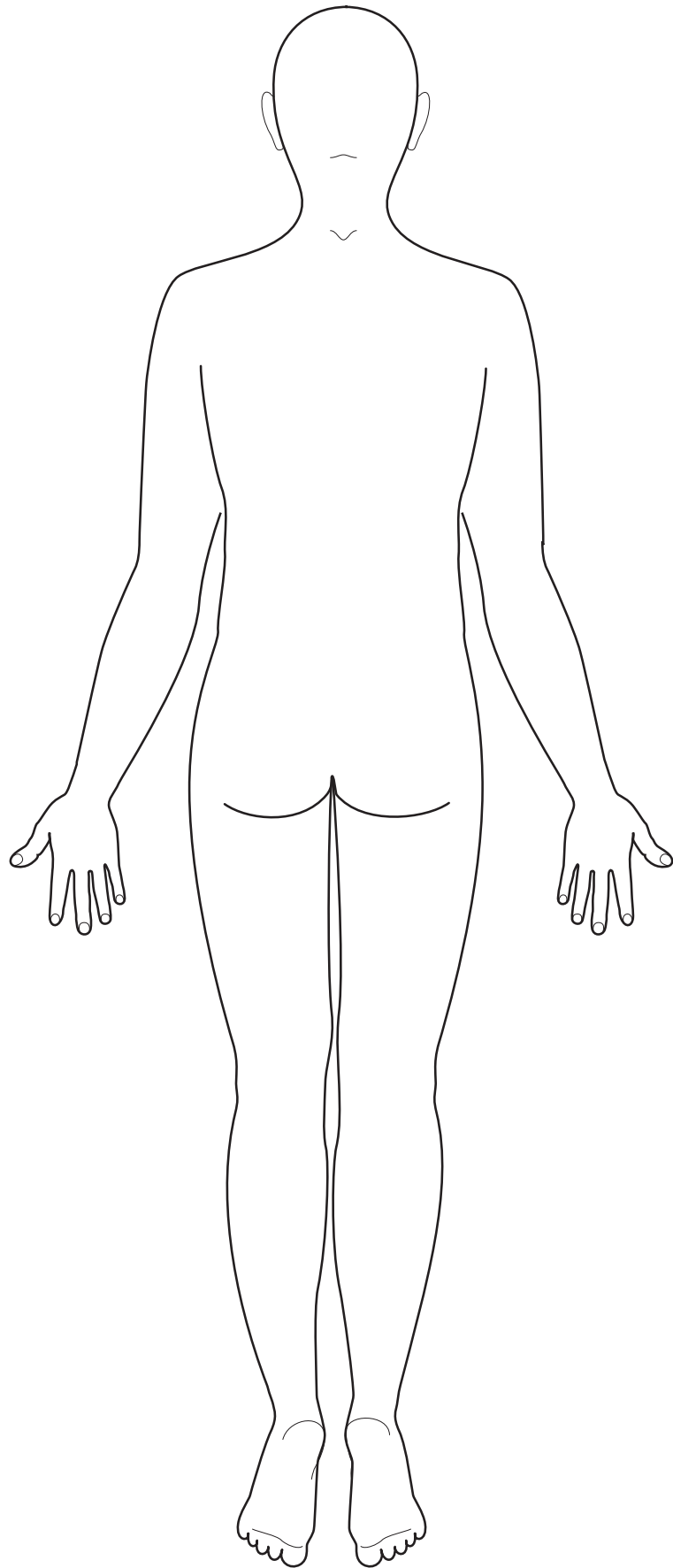
(xxiii) Brain — coronal slices





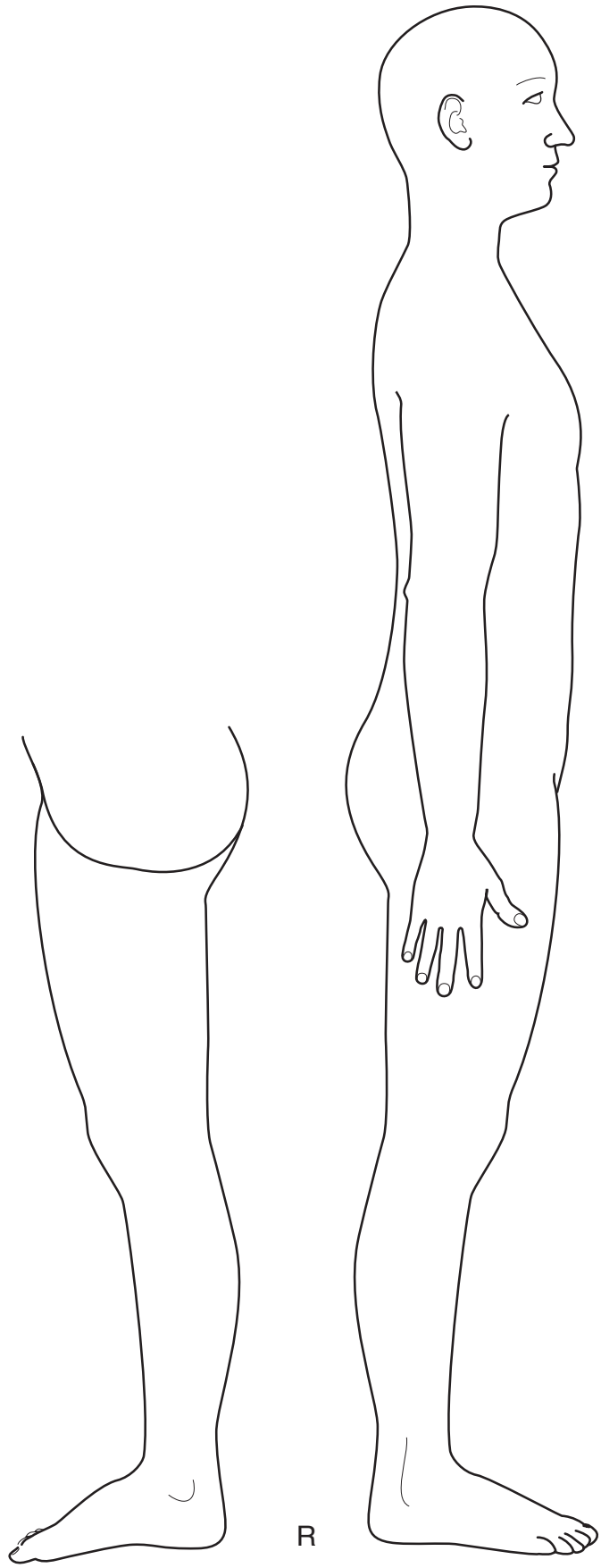




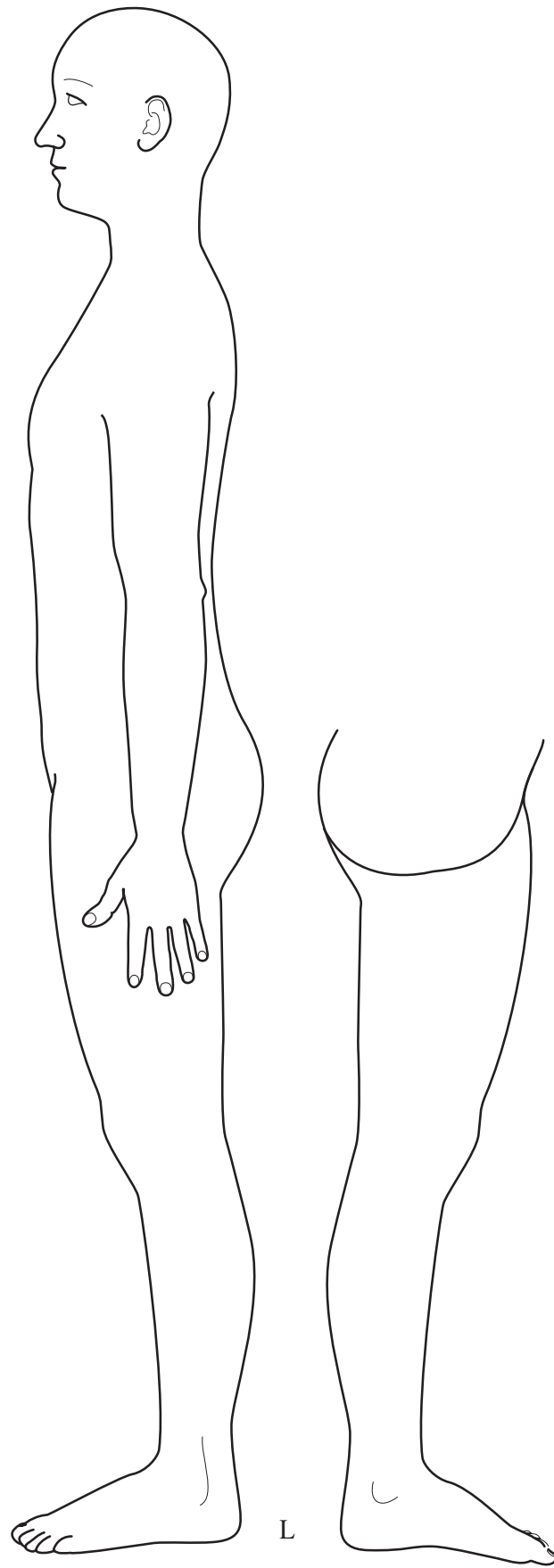






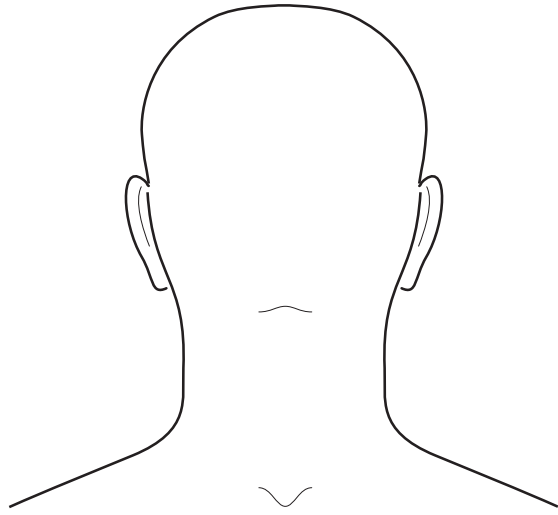
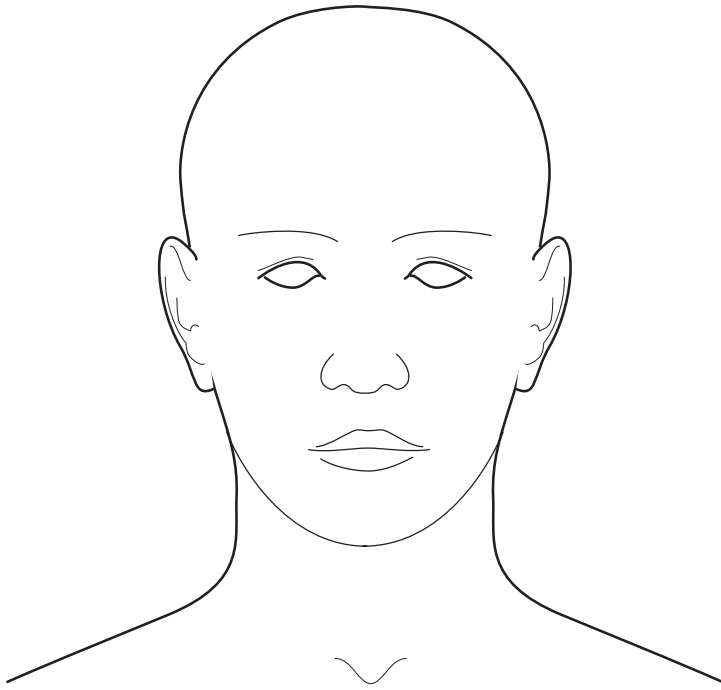




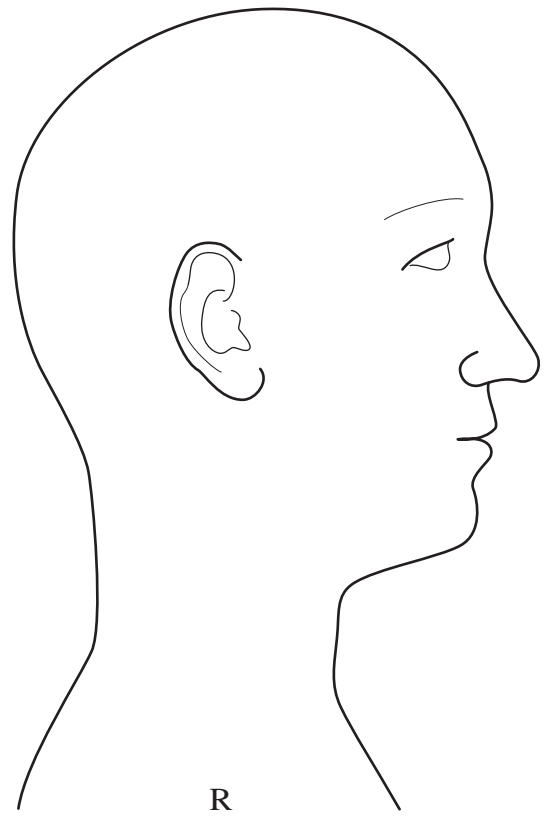
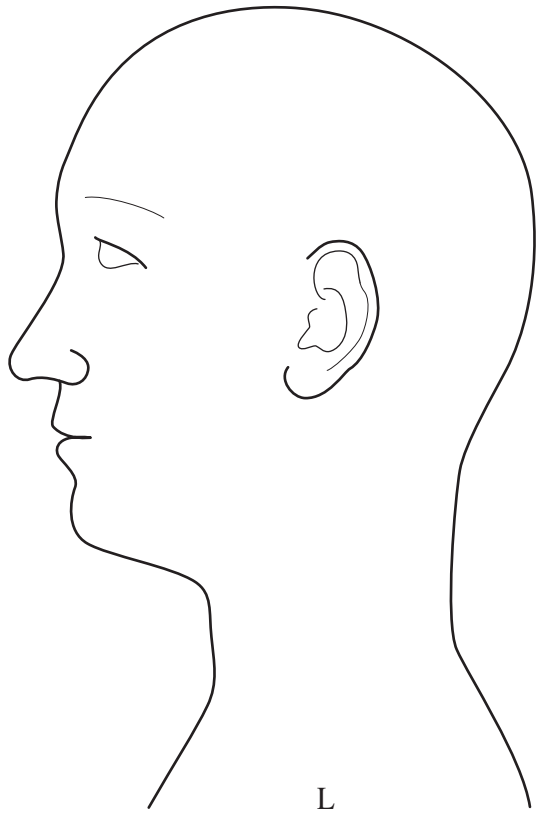


L



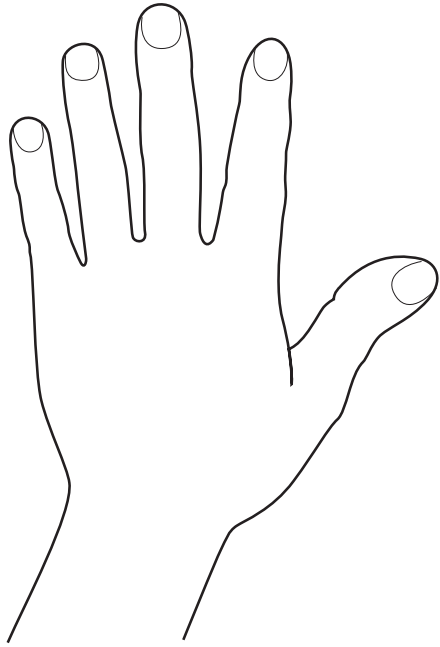




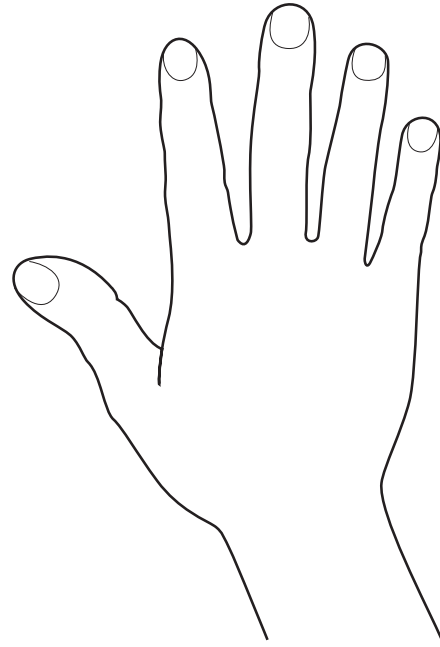










L



R

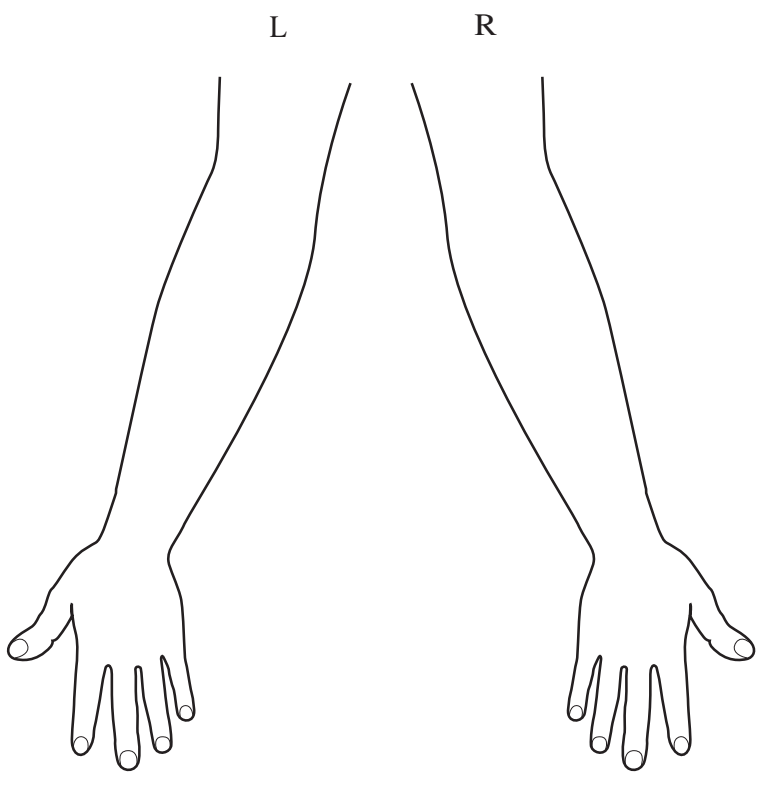
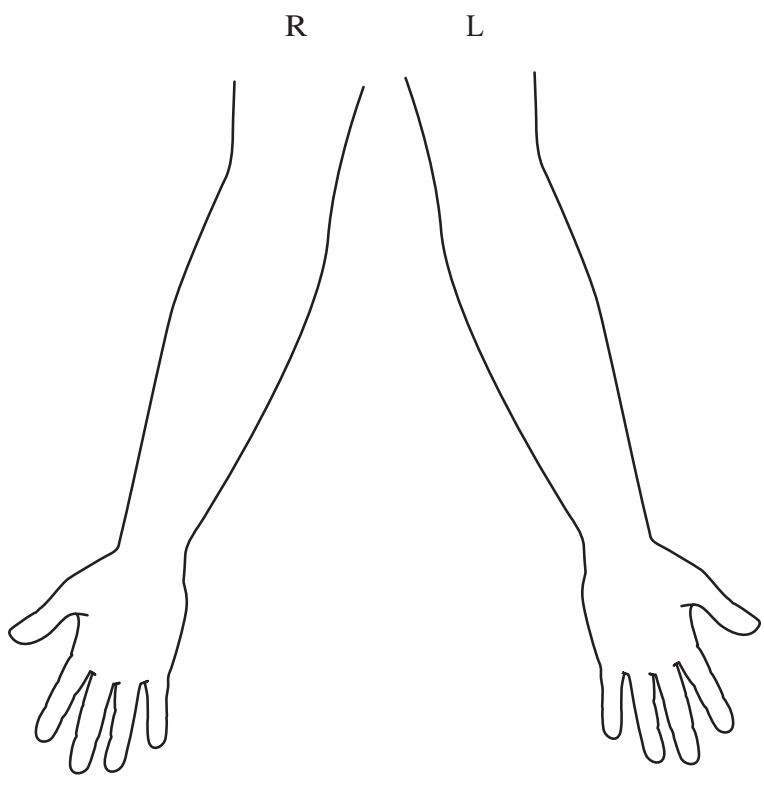


L

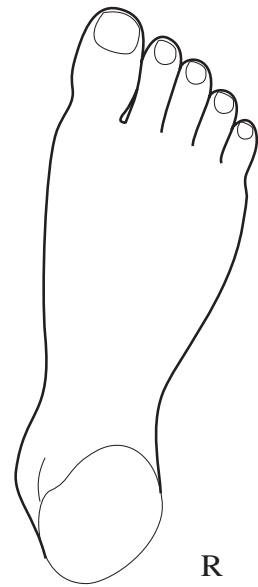
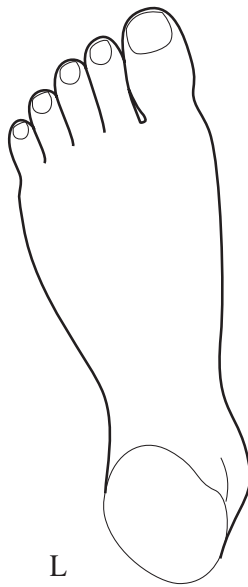
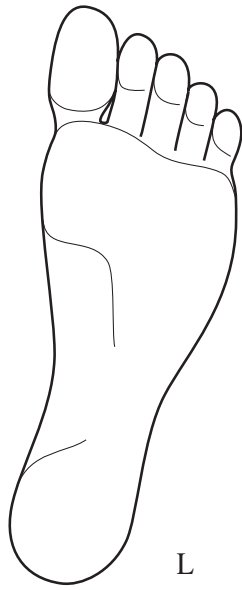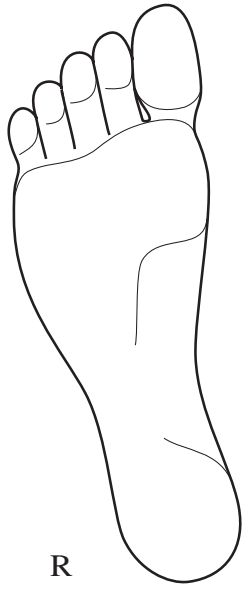


R

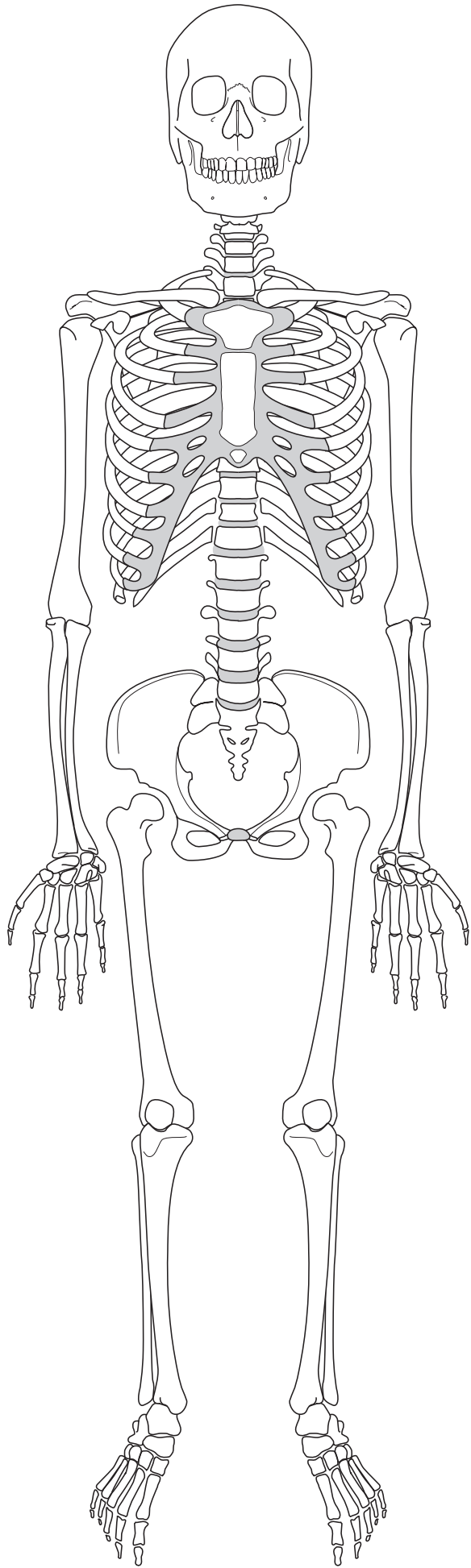






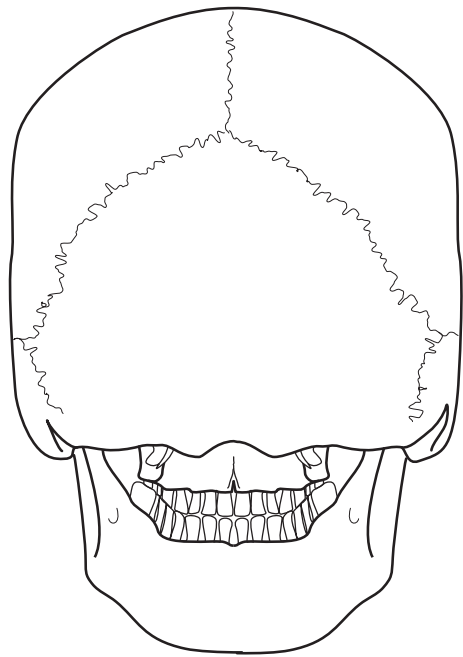
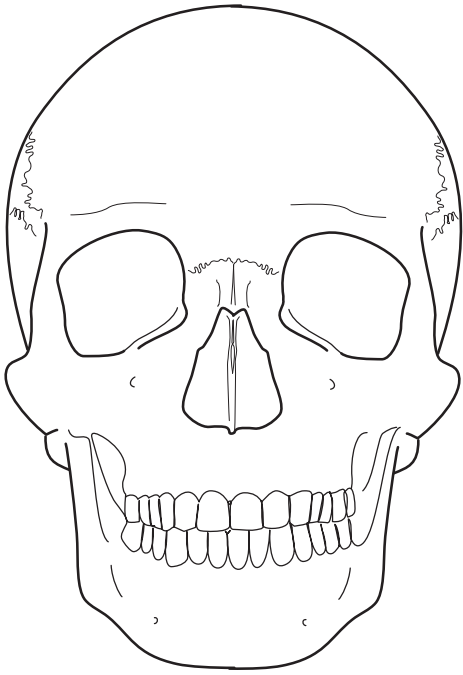




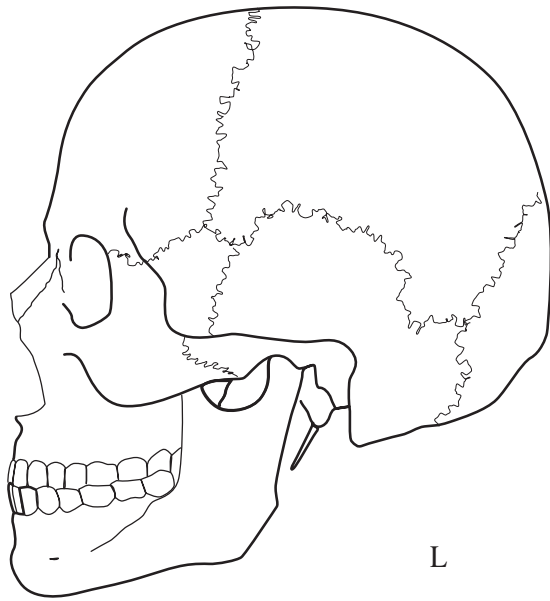




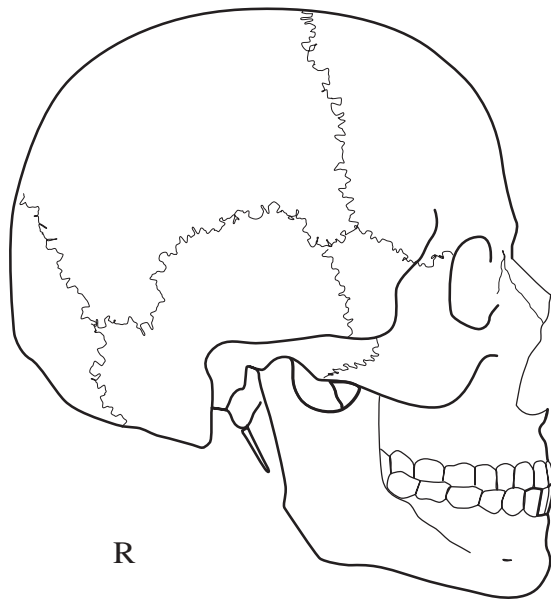






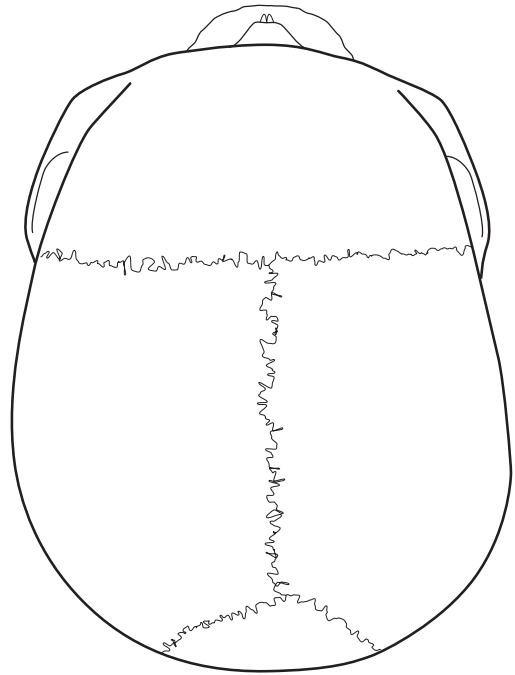
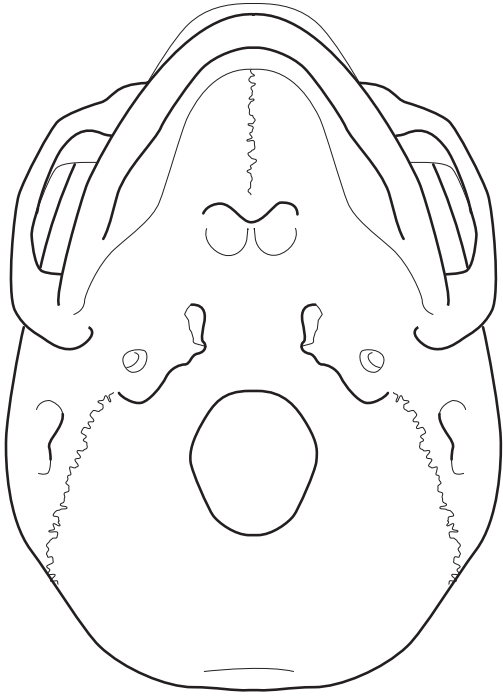


L

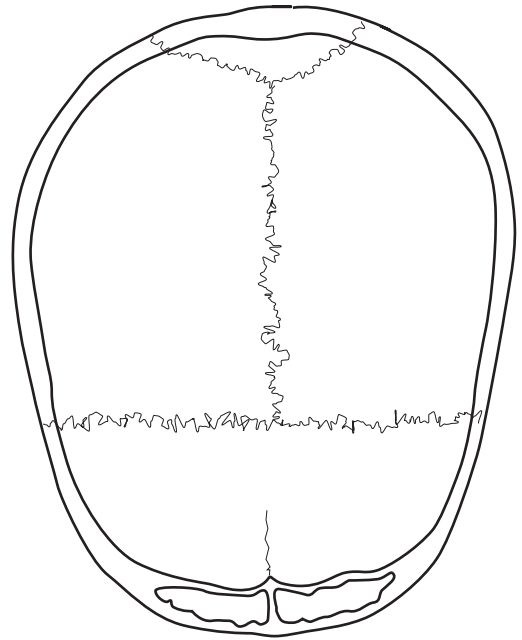
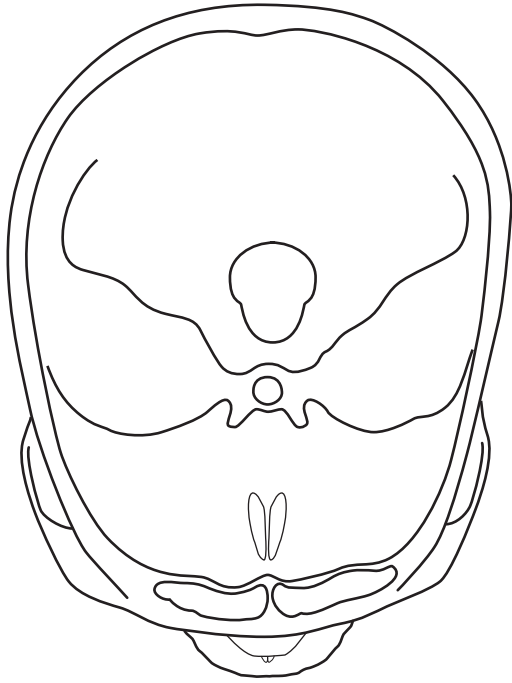


R



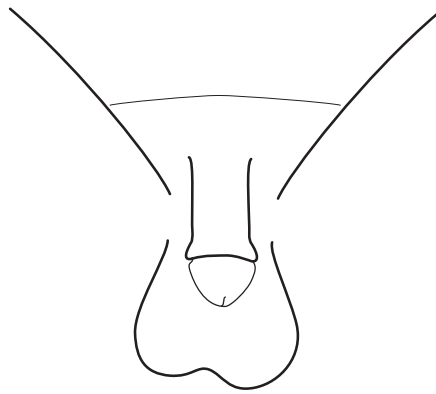
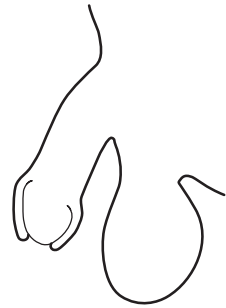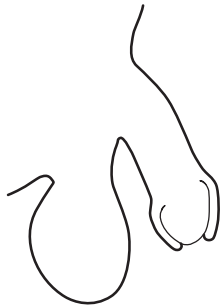
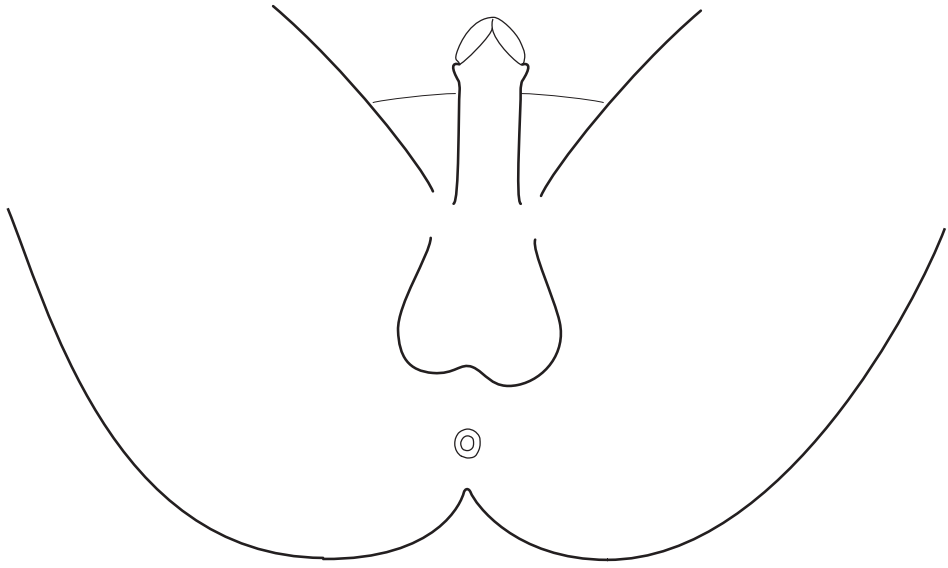




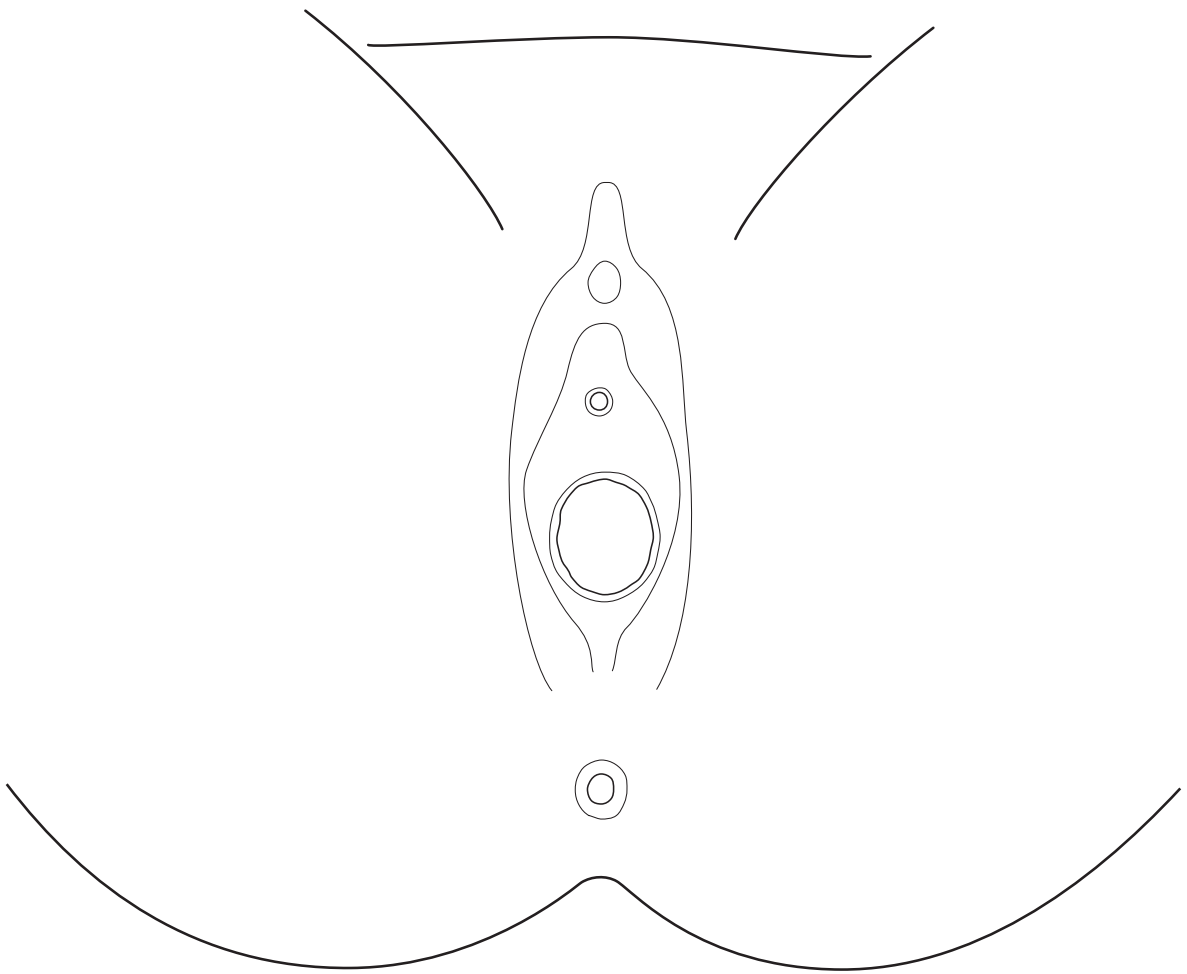




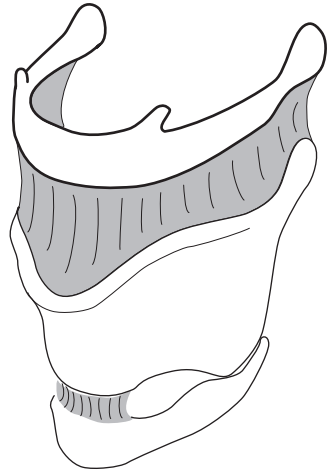
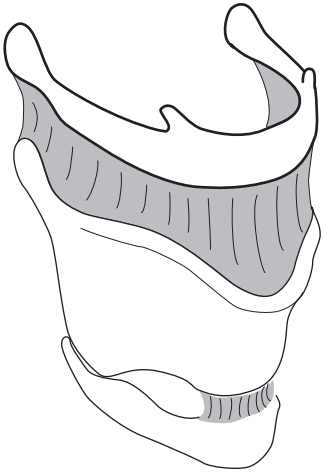
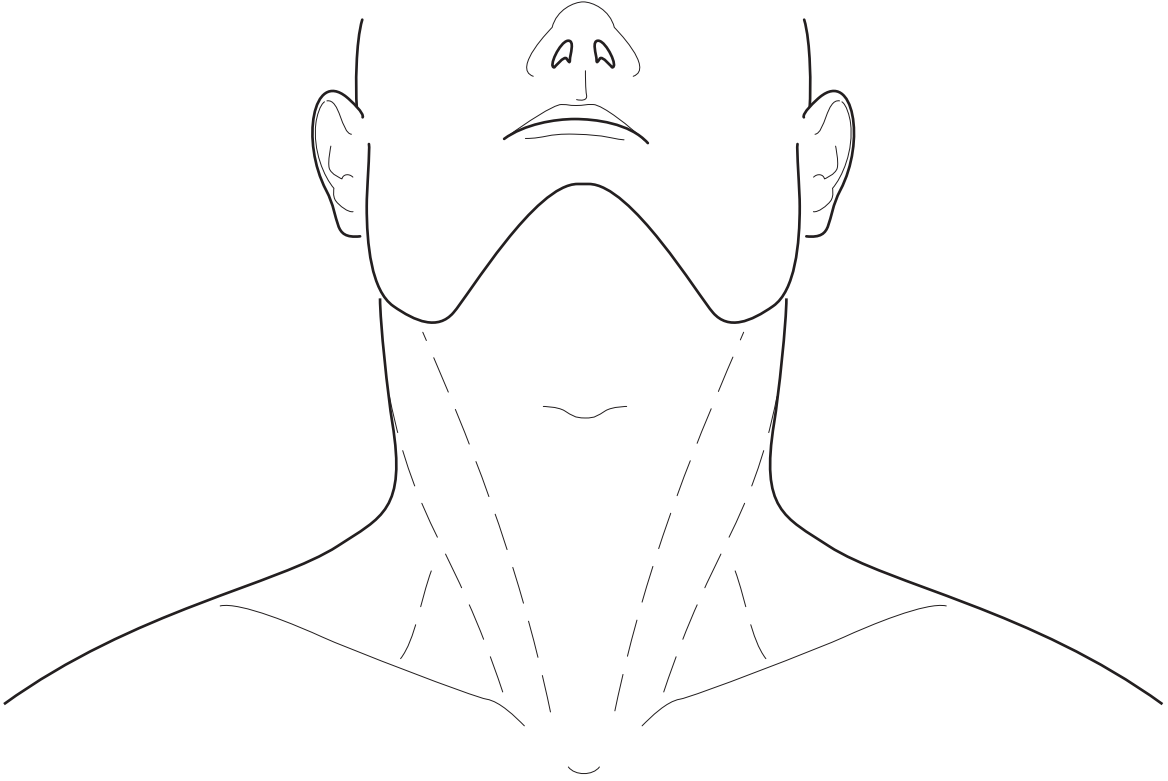





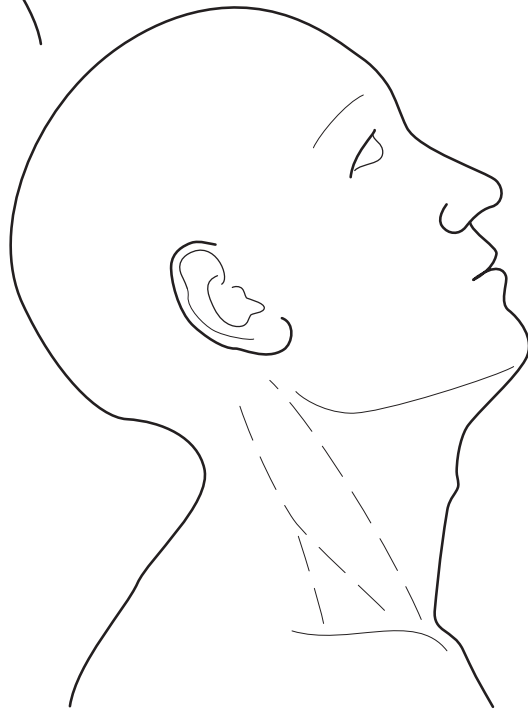
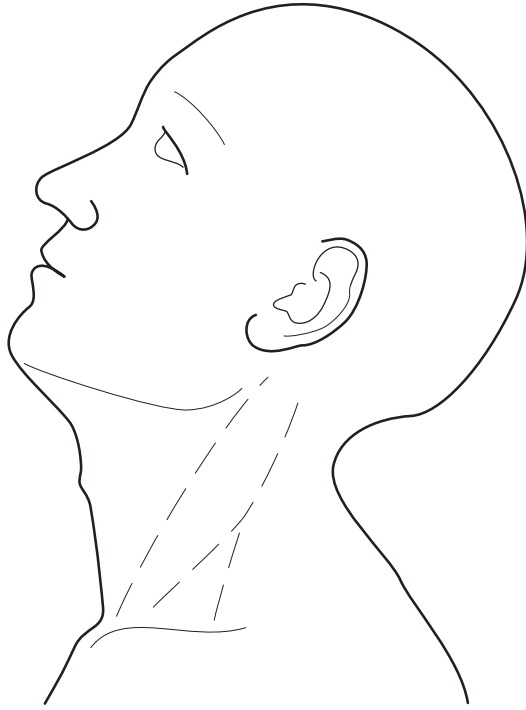



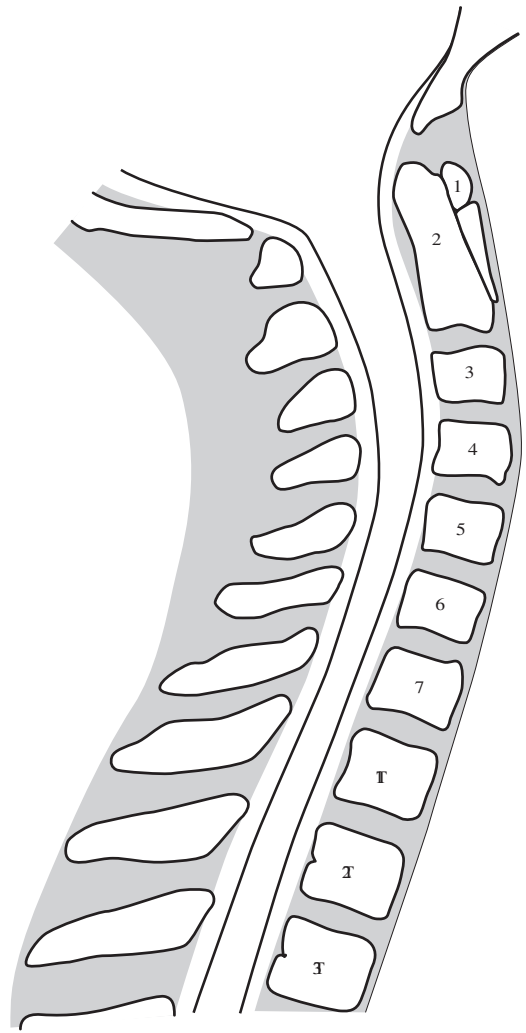
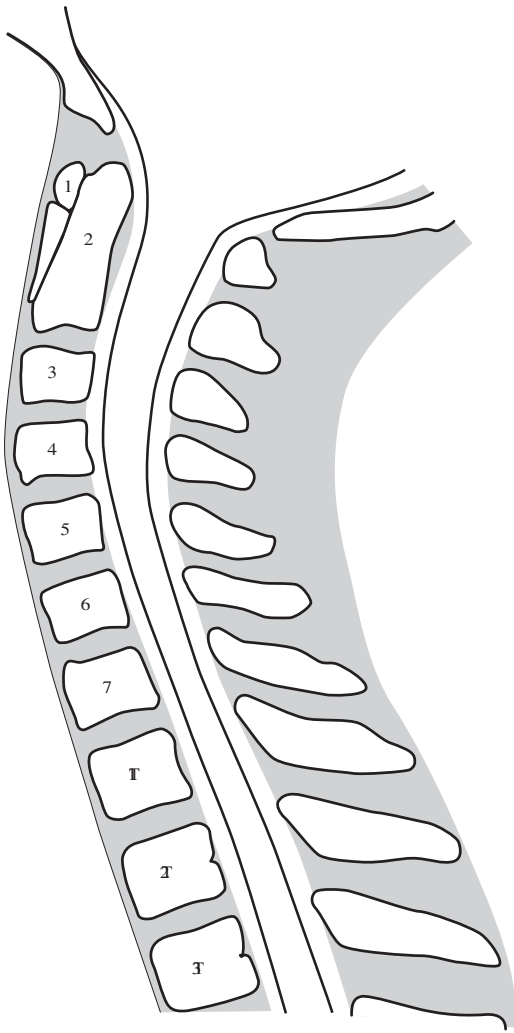




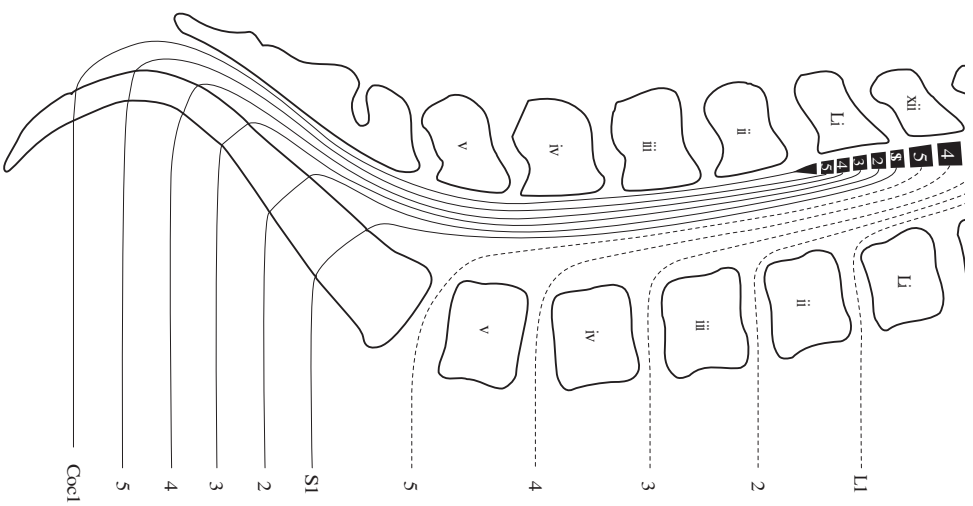
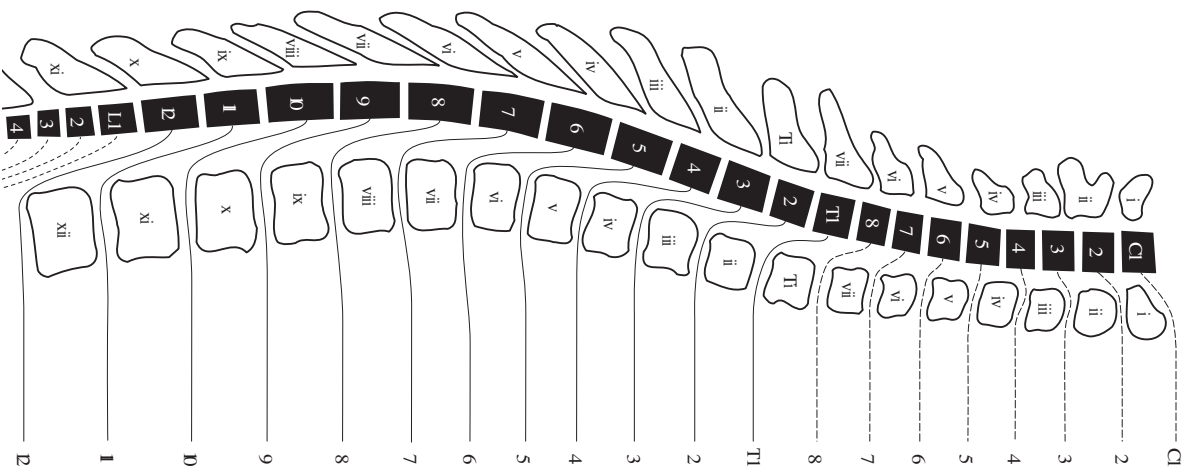
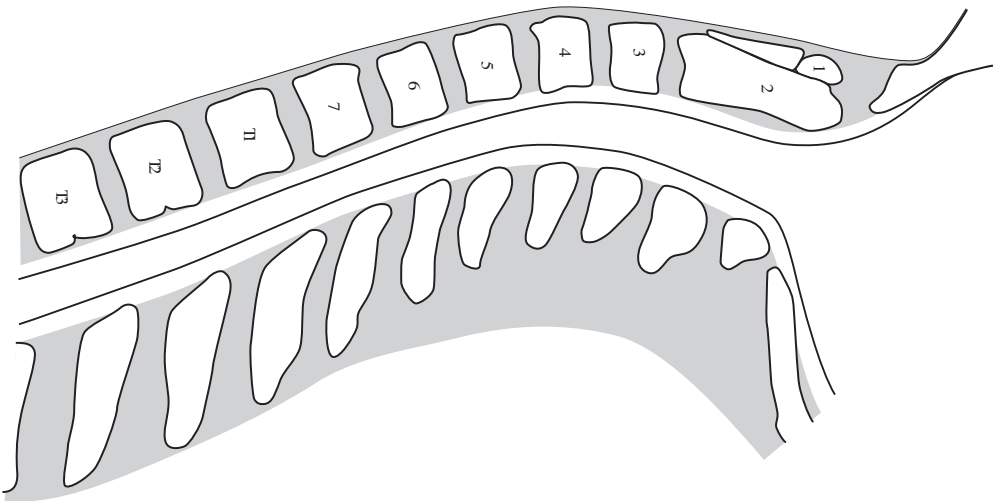




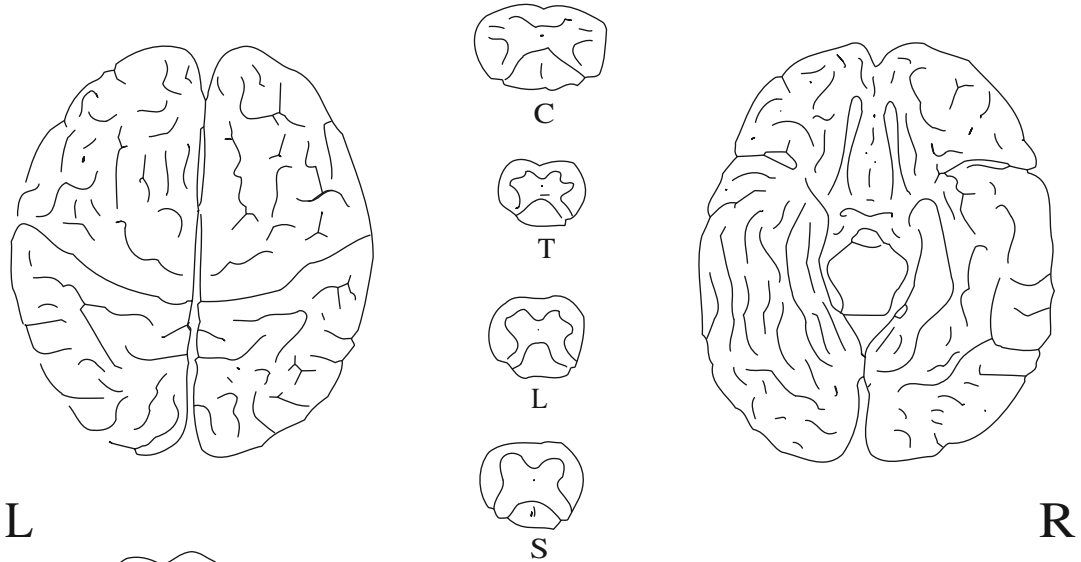
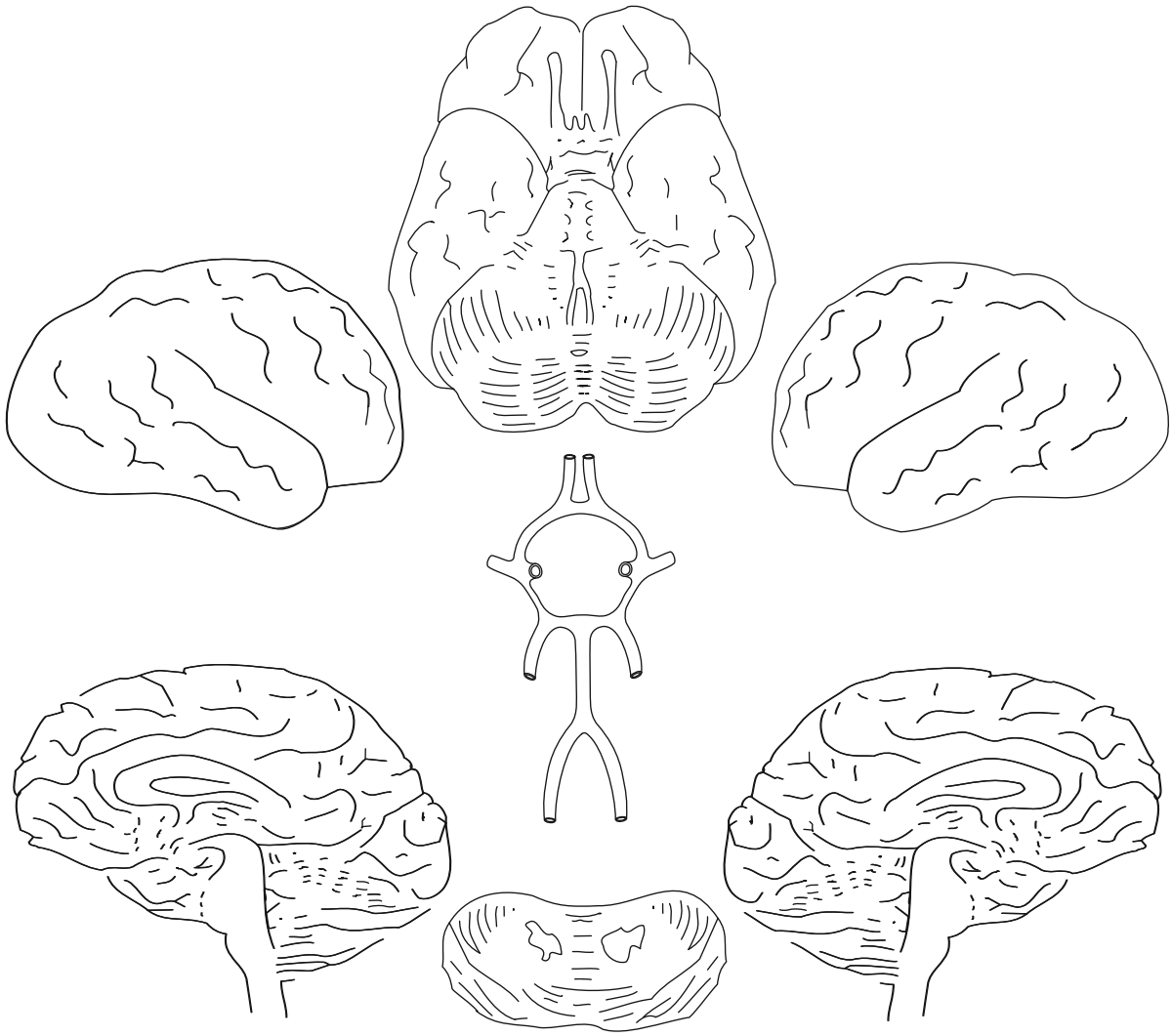






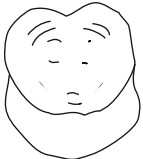






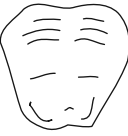L

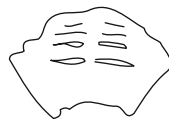R



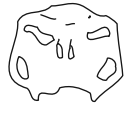midbrain



pons

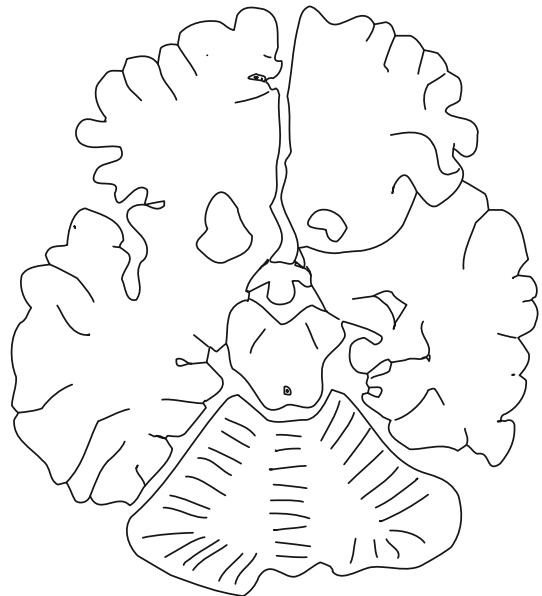
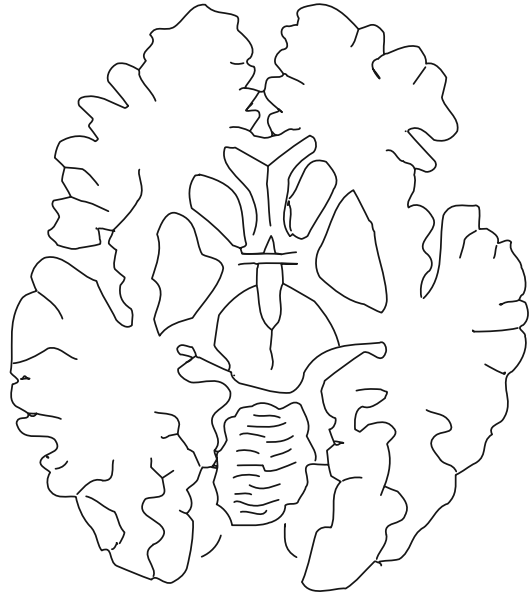
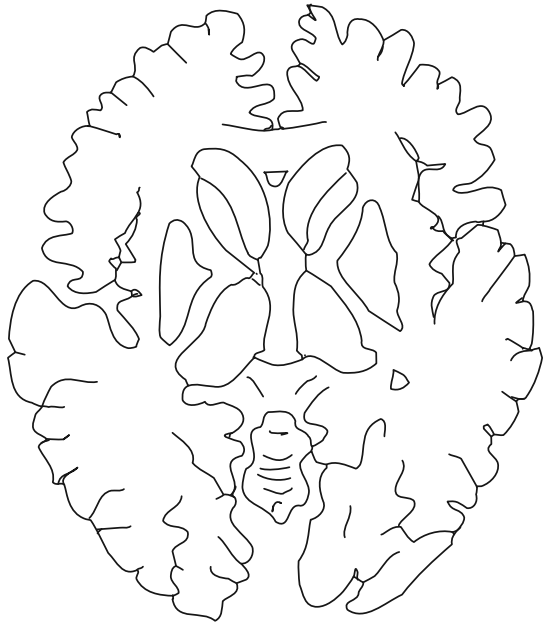
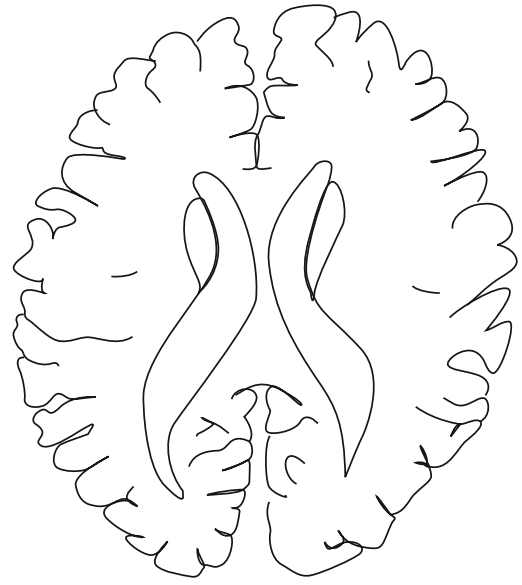
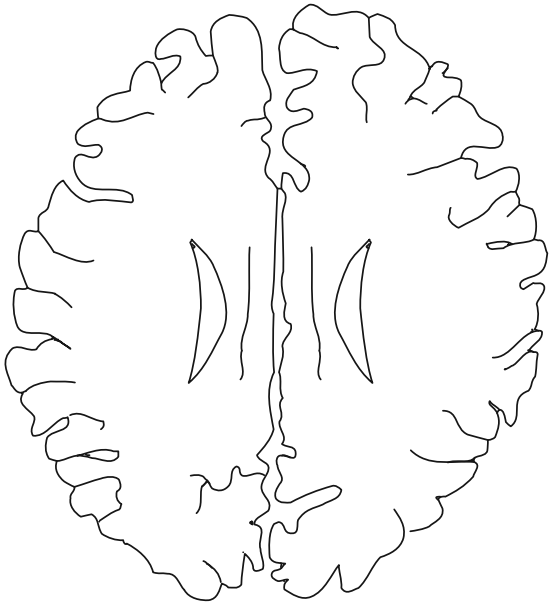


low pons



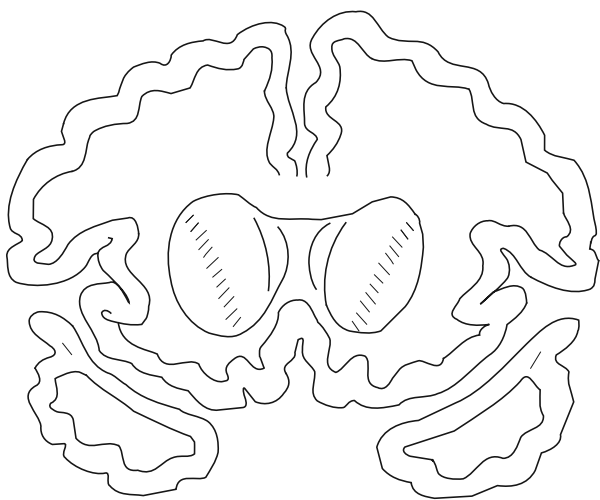
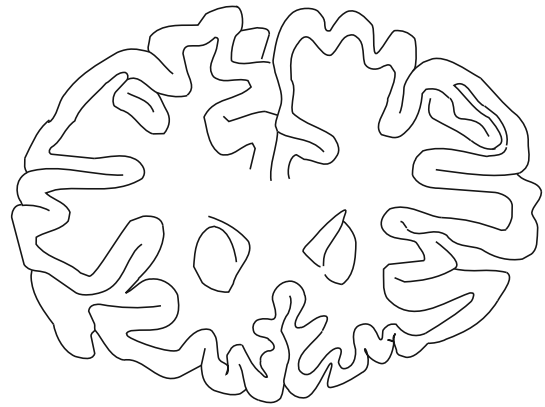
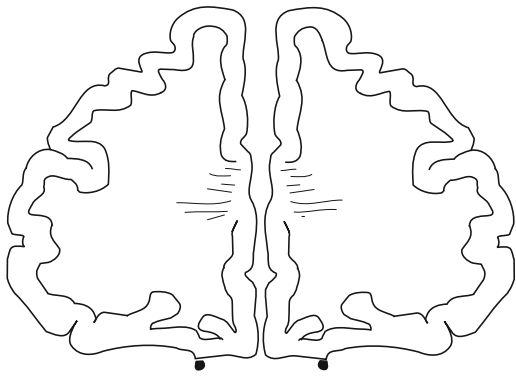
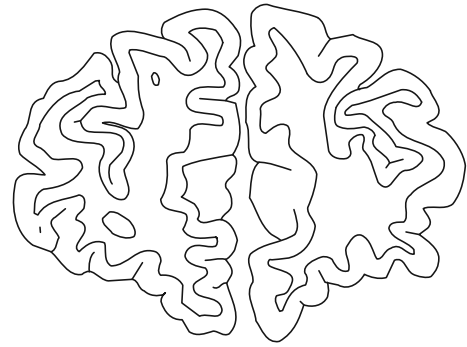
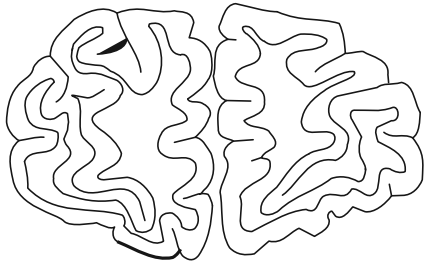
medulla





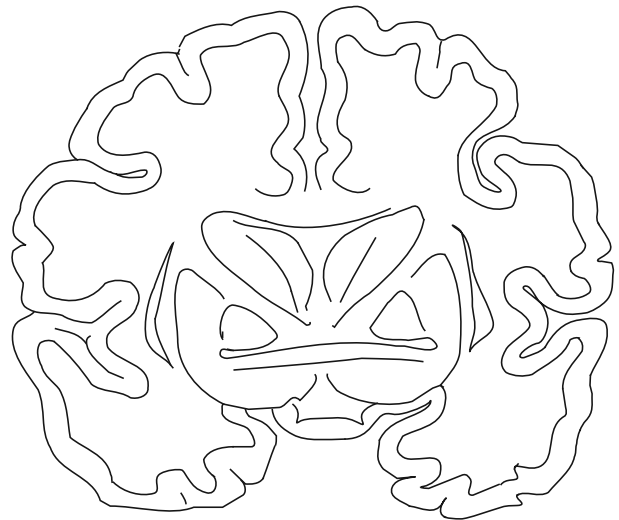





L

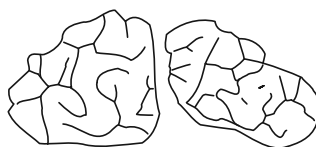
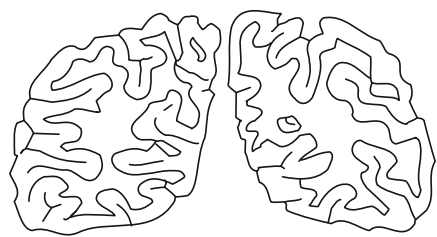
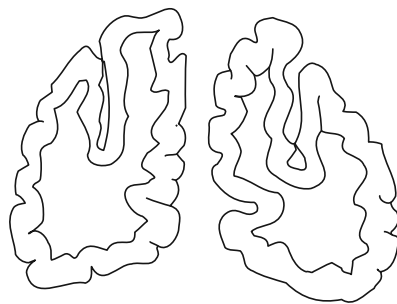
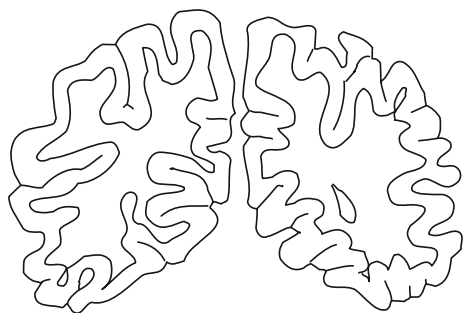
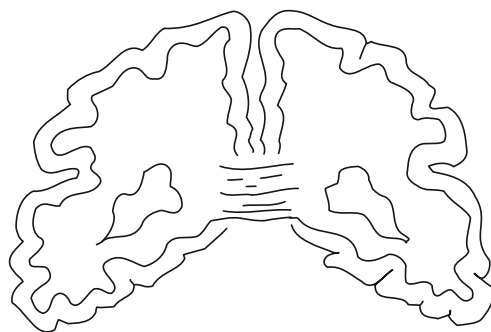
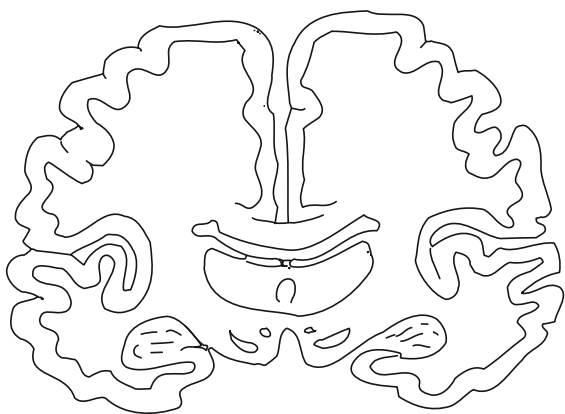
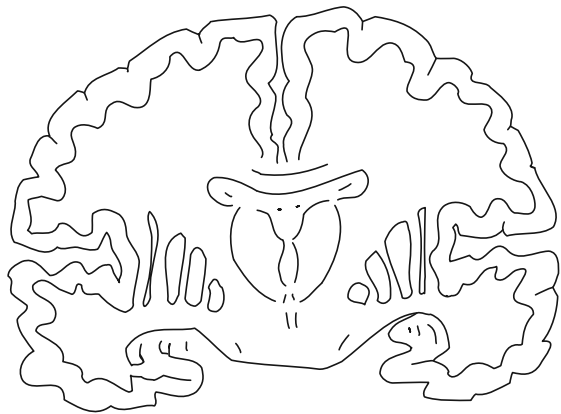
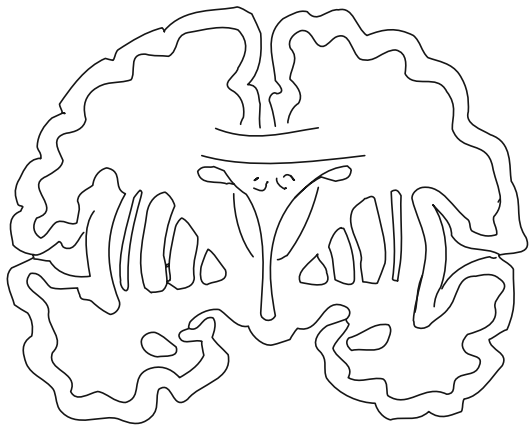
R



L

R





L

R

L

R



# Notes

---



# Notes

---





**Past medical history:**

.....  
.....  
.....  
.....  
.....  
.....

Drugs/Medication .....

.....  
.....

**Medical examination:**

Pulse rate: .....

B P : ..... / .....

temp: ..... °C

Ht: ..... cm

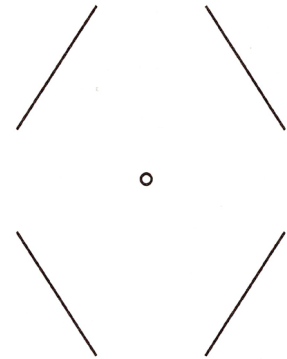
Wt: ..... Kg

Morphometry .....

.....  
.....

**General medical examination:**

.....  
.....  
.....  
.....  
.....



**Records of Findings:**

X rays

Photography

Video

Other .....

**Examiner:**

Name .....

Signature .....

Professional Address .....

Time ..... hrs Date ..... / ..... / .....

Tel ..... Fax .....

**Notes on wound description:**

1. In describing a wound consider the following features:

<b>Site</b>	<b>Colour</b>	<b>Age</b>
<b>Size</b>	<b>Contours</b>	<b>Borders</b>
<b>Shape</b>	<b>Course</b>	<b>Classification</b>
<b>Surrounds</b>	<b>Contents</b>	<b>Depth</b>

2. Ensure descriptions are consistent with the following definitions:

- Abrasion** – A superficial scraping injury of the body surface with or without bleeding
- Bruise** – Leakage of blood from blood vessels discolouring the tissues of the body
- Incision** – A cutting type injury that severs tissues in a clean and generally regular fashion
- Laceration** – A tear or split in tissues

- 3. All descriptions of wounds and injuries should be made by reference to the subject in the standard anatomical positions.
- 4. The use of terms such as Superior, Inferior, Anterior and Posterior should refer to the subject in standard anatomical position.
- 5. The measured position of wounds on the body should be located by reference to fixed bony landmarks.
- 6. The accurate classification of a wound type has major significance for determining injury causation.
- 7. An accurate Forensic Medical examination should assist in the reconstruction of the events in which the injury occurred.

Anatomical Figuring has been prepared by the Victorian Institute of Forensic Medicine as a photocopiable resource of simplified body charts for use by forensic pathologists, medical practitioners, lawyers and students.

The simple style and high quality of the diagrams provides an ideal base for recording injuries and other body features.

© 2015 Copyright on this material is held by the Victorian Institute of Forensic Medicine. Use for professional practice and study purposes is allowed by the VIFM.

ISBN 0 7306 7935 7