



Cardiac cysticercosis and neurocysticercosis in sudden and unexpected community deaths in Lusaka, Zambia: a descriptive medico-legal post-mortem examination study[☆]

Cordilia Himwaze^{a,*}, Luchenga Adam Mucheleng'anga^{b,d}, Victor Telendiy^b, Amos Hamukale^c, John Tembo^d, Nathan Kapata^d, Francine Ntouni^e, Alimuiddin Zumla^{d,f}

^a University Teaching Hospital, Department of Pathology and Microbiology, Lusaka, Zambia

^b Ministry of Home Affairs, Office of the State Forensic Pathologist, Lusaka, Zambia

^c Zambia Field Epidemiology Training Program, Lusaka, Zambia

^d UNZA-UCLMS, PANDORA-ID-NET and HERPEZ R&D Program, University Teaching Hospital, Lusaka, Zambia

^e Fondation Congolaise pour la Recherche Médicale (FCRM), Faculty of Sciences and Technology, University Marien Ngouabi, Brazzaville, Republic of Congo

^f Division of Infection and Immunity, University College London; NIHR Biomedical Research Centre, UCLHospitals NHS Foundation Trust, London, UK

ARTICLE INFO

Article history:

Received 7 November 2021

Revised 25 November 2021

Accepted 27 November 2021

KEYWORDS:

Cysticercosis

Cardiac

Heart

Brain

Forensic autopsy

Community deaths

Neurocysticercosis

Cardiac cysticercosis

Zambia

Africa

ABSTRACT

Background: Cysticercosis is a World Health Organization designated neglected human zoonosis worldwide. Data on cardiac cysticercosis and its contribution to sudden and unexpected community deaths are scarce and require study.

Methods: A study was performed of cysticercosis-related deaths and other incidental cases of cysticercosis seen at forensic post-mortem examination over a period of 12 months, in individuals who died suddenly and unexpectedly in the community in Lusaka, Zambia. Whole-body post-mortem examinations were performed according to standard operating procedures for post-mortem examinations. Representative samples were obtained from all body organs and subjected to histopathological examination. Information was obtained on circumstances surrounding the death. Data were collated on patient demographics, history, co-morbidities, pathological gross and microscopic findings, and forensic autopsy cause(s) of death. The available literature on cardiac cysticercosis was also reviewed.

Results: Nine cases of cysticercosis were identified. Eight of the nine cases had cardiac cysticercosis. There was no prior history of cysticercosis before death. All were male, aged between 28 and 56 years, and from high population density and low socioeconomic communities. There was no community case clustering identified.

Conclusions: Cardiac cysticercosis and neurocysticercosis are important incidental findings in sudden and unexpected deaths in the community and can easily be missed antemortem. More investment in forensic autopsy services is required to define the undiagnosed burden of deaths due to treatable communicable diseases.

© 2022 The Authors. Published by Elsevier Ltd on behalf of International Society for Infectious Diseases.

This is an open access article under the CC BY-NC-ND license (<http://creativecommons.org/licenses/by-nc-nd/4.0/>)

1. Introduction

Sudden and unexpected deaths in any community can be due to a range of underlying conditions including communicable diseases

not detected antemortem. Mandated by law, these deaths are subject to forensic medico-legal examination, which provides an opportunity to study underlying causes of death in the community.

Cysticercosis caused by the pig tapeworm *Taenia solium* remains an important parasitic zoonotic disease affecting males and females equally across all age groups worldwide (Dixon et al., 2020; Sorvillo and DeGiorgio, 2020; Sorvillo et al., 2011; Phiri et al., 2003; Schantz et al., 1988; Garcia and Del Brutto, 2005). Human cysticercosis occurs when food or water contaminated with *T. solium* ova are ingested (WHO, 2021). In the stomach, the ova hatch into larvae, penetrate through the gut wall, and spread via the blood-

[☆] Cordilia Himwaze, Luchenga Adam Mucheleng'anga, and Alimuiddin Zumla contributed equally.

* Corresponding author: Cordilia Himwaze, University Teaching Hospital, Department of Pathology and Microbiology, Nationalist Road, Lusaka, Zambia. Tel: +260971836812.

E-mail address: cordeliahimwaze@gmail.com (C. Himwaze).

stream to various tissues and organs forming vesicular translucent cysts. Autoinfection involves the retrograde movement of proglottids of a gut tapeworm infestation from the intestines into the stomach, with subsequent release of *T. solium* larvae.

The clinical features of human cysticercosis range from sub-clinical asymptomatic to mild morbidity, severe morbidity, and sometimes death (WHO, 2021; CDC, 2021). These are determined by the location of the cysts in the body and the overall cyst burden. Any organ can be affected, although it has a predilection for the central nervous system. Globally, cysticercosis is the most common parasitic disease affecting the central nervous system presenting with neurological symptoms and adult-onset seizures (WHO, 2021; CDC, 2021; Nash and Garcia, 2011; Abanto et al., 2021; Wallin and Kurtzke, 2004), and it is sometimes associated with sudden death (Esberg and Reske-Nielsen, 1988; Hortobágyi et al., 2009). Whilst there is abundant literature on neurocysticercosis from all continents, reports of cardiac cysticercosis have been scarce (Hortobágyi et al., 2009; Spina et al., 2013; Eberly et al., 2008). This may be due to subclinical, cryptic presentations or a lack of clinical awareness of the possibility of cysticercosis (Kalra et al., 2019; Jain et al., 2010; Nery et al., 2018; Jain et al., 2010; Bhalla et al., 2008). Cardiac cysticercosis has been reported as a rare cause of myocardial infarction (Nery et al., 2018).

This study presents data on cases of cardiac cysticercosis and neurocysticercosis seen at forensic post-mortem examination over a period of 12 months, in individuals who died suddenly and unexpectedly in the community in Lusaka, Zambia.

2. Methods

2.1. Ethics and permission

In Zambia, forensic autopsies are mandated by law and are conducted through an Order for Post-mortem Examination of sudden and unexpected deaths in the community. Data from forensic autopsies are stored at the Office of the State Forensic Pathologist (OSFP). The OSFP gave permission for the use of anonymized data.

2.2. Study design

This was a retrospective case analysis of whole-body forensic post-mortem examinations performed over a period of 12 months on people who died suddenly and unexpectedly in the community of Lusaka, Zambia. These cases were referred to the OSFP at the University Teaching Hospital (UTH) for forensic post-mortem examination. Information on circumstances surrounding the death was obtained from the next of kin by the forensic pathologist, as per procedure, before the post-mortem examination. Data were extracted from autopsied cases where cysticercosis was found to be a proximate cause of death or an incidental co-morbid autopsy finding.

2.3. Forensic autopsy procedures

Forensic safety and autopsy protocols were followed, as described previously (Mucheleng'anga et al., 2021). Briefly, the whole-body autopsies were performed by a forensic pathologist (L.A.M.) and an anatomical pathologist (C.H.) according to the guidelines of the OFSP Zambia Practice Manual for Medico-legal Death Investigations.

2.4. Tissues sampled and histological examination

Representative samples were obtained from the brain, lung, heart, liver, spleen, kidney, gastrointestinal tract, and muscles and submitted in standard tissue cassettes. These were fixed in 10%

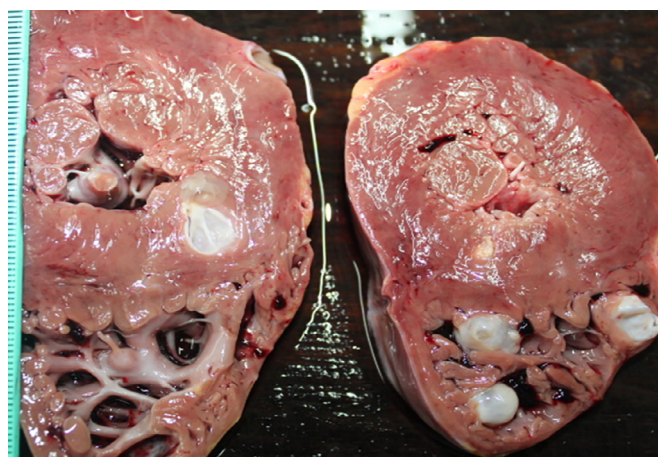


Figure 1. Multiple *Taenia solium* cysts in the heart wall and cavities.

neutral buffered formalin for 72 hours. Samples were embedded in paraffin, sectioned, mounted onto glass slides, and stained with hematoxylin and eosin (H&E) and were examined microscopically. All slides were examined by both the forensic and anatomical pathologists.

2.5. Cause(s) of death

The decedents' demographics, history, circumstances, and autopsy findings were recorded. The cause(s) of death were formulated within the context of the circumstances surrounding the death, history of the case, autopsy findings, and ancillary studies.

2.6. Data collection and analyses

All cases of cysticercosis were identified. The decedents' demographics, geographical place of residence, history of ill health (where available), circumstances surrounding the death, post-mortem examination findings, and opinion of the cause of death was entered into Excel 2020 and analyzed using Stata version 14.

3. Results

3.1. Demographics of cysticercosis cases and case details

Table 1 summarizes the demographics and autopsy findings of the nine cases of cysticercosis identified. They had all died suddenly and unexpectedly and were brought-in-dead (BID) and others as suspected homicides. There was no prior history of cysticercosis before death. All were male, aged between 28 and 56 years, and from high population density and low socioeconomic communities. There was no identifiable case clustering. Whilst two cases were from the same Lusaka residential area, the other seven decedents resided in different geographical locations (compounds) of Lusaka. A common feature was alcohol abuse (eight out of nine cases) and frequenting beer bars/halls where grilled pork is served.

3.2. Gross pathology and microscopic findings

T. solium cysts were seen as single or multiple lesions, round or ovoid, 1 mm to 25 mm in size, randomly distributed in the heart, brain, and other organs and tissues.

Representative images of gross autopsy and microscopic findings of cardiac cysticercosis are shown in Figures 1–4 and those of brain cysticercosis in Figures 5–7. Figure 8 shows a *T. solium* cyst.

Table 1
Cysticercosis seen at forensic autopsy: decedents' demographics, autopsy findings, and causes of death

Decedents' demographics					Presence and location of <i>Taenia solium</i> cysts						AutopsyCause(s) of death
Case No.	Sex	Age (years)	Residence—Lusaka district location	Alcohol abuse	Heart	Brain	Lung	Diaphragm	Muscles	Omentum	
1	M	34	Misisi	Yes	Present	Present	Present	Present	Present	Present	Cardiac cysticercosis
2	M	42	Central business district	Yes	Present	Present	Absent	Absent	Absent	Absent	Blunt impact trauma to the head due to assault
3	M	26	George	Yes	Present	Present	Absent	Absent	Absent	Absent	cardiac cysticercosis
4	M	35	Chilenje	Yes	Present	Present	Present	Present	Absent	Absent	Cardiac cysticercosis and neurocysticercosis
5	M	56	Kanyama	No	Present	Present	Present	Absent	Absent	Absent	Cardiac cysticercosis and neurocysticercosis
6	M	40	Soweto	Yes	Present	Present	Present	Absent	Absent	Present	Cardiac cysticercosis and neurocysticercosis
7	M	51	Kanyama	Yes	Present	Present	Present	Absent	Absent	Absent	acute alcohol intoxication in a man with cardiac cysticercosis and neurocysticercosis.
8	M	28	Ng'ombe	Yes	Present	Absent	Absent	Absent	Absent	Absent	Cardiac cysticercosis/ bronchopneumonia/chronic alcoholism
9	M	55	Zingalume	Yes	Absent	Present	Absent	Absent	Absent	Absent	Acute pyelonephritis in a man with neurocysticercosis

M, male.

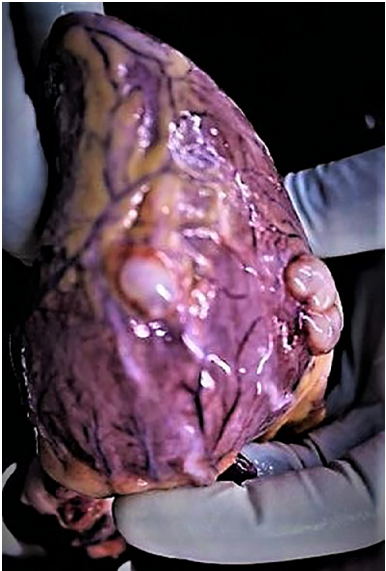

Figure 2. Multiple *Taenia solium* cysts on the surface of the heart.

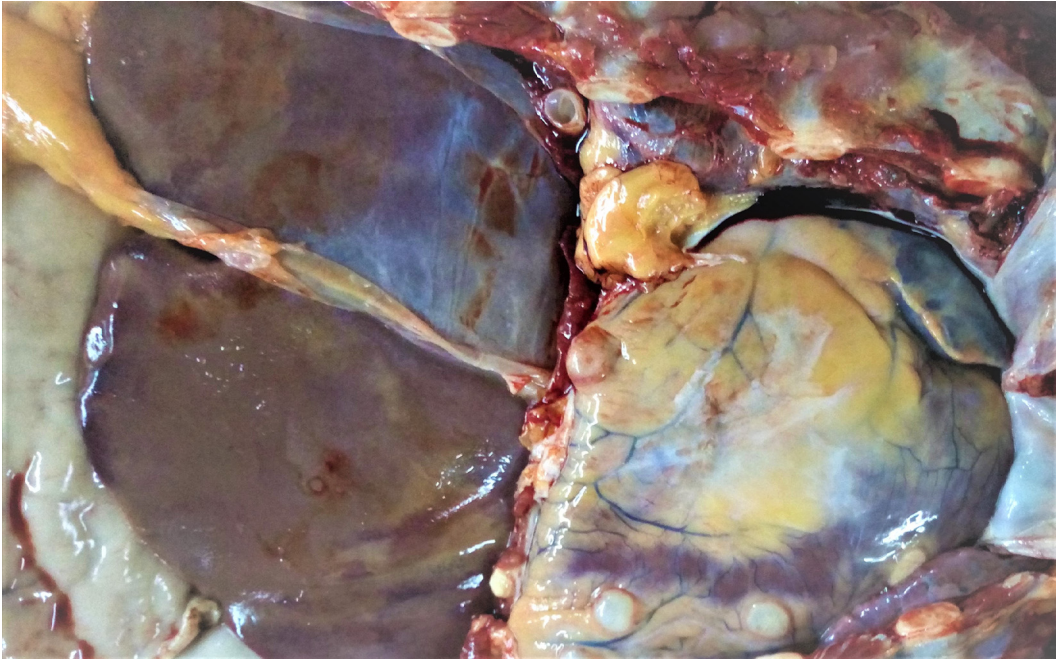


Figure 3. Multiple *Taenia solium* cysts on the heart surface and peritoneum.

All cysticercosis cases microscopically showed racemose cysticerci with a convoluted, intact or degenerated, and hyalinized cysticercal wall.

3.3. Case history and autopsy findings

Case 1 was a 34-year-old male who was found dead at home. He was an alcoholic with no prior history of ill health. There was

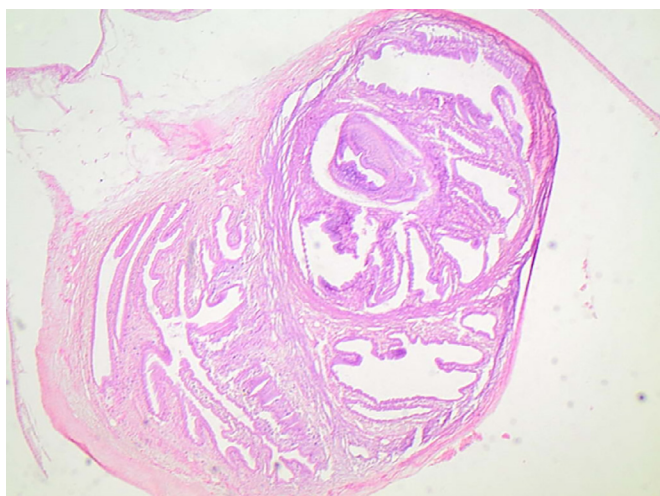


Figure 4. Racemose cysticercus with a convoluted, degenerated, and hyalinized cysticercal wall (H&E stain, magnification $\times 4$).

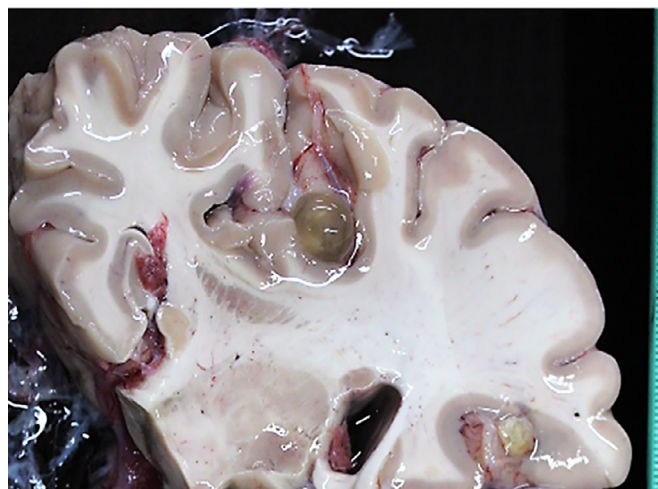

Figure 6. Cysts of *Taenia solium* located in the brain sulci.

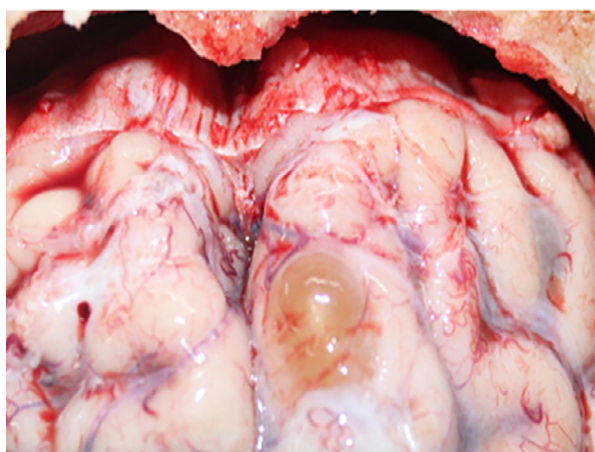

Figure 5. Cyst of *Taenia solium* protruding from the brain gyrus.

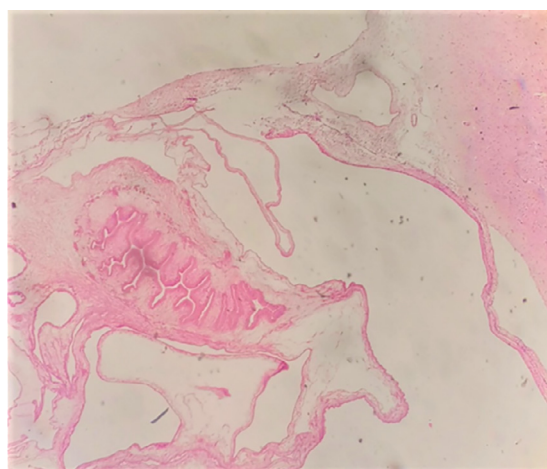


Figure 7. Histopathology of a brain cyst. Racemose cysticercus with a convoluted, degenerated, hyalinized cysticercal wall (H&E stain, magnification $\times 10$).

no evidence of overdose, trauma, seizures, or poisoning. The autopsy examination showed multiple translucent *T. solium* cysts containing serous fluid and whitish particles in the heart muscles, neck muscles, diaphragm, and omentum. Microscopic examination showed racemose cysticerci with convoluted, intact or degenerated, and hyalinized cysticercal walls. The cause of death was cardiac cysticercosis.

Case 2 was a 42-year-old male, known alcoholic, who was found dead in the street with bruises on his body. The autopsy showed blunt impact trauma to the head, chest, and extremities. At autopsy, the heart muscles showed multiple translucent *T. solium* cysts. The cause of death was blunt impact trauma to the head due to assault in a man with cardiac cysticercosis.

Case 3 was a 26-year-old male, known alcoholic, with no history of ill health, who died during a minor altercation. The autopsy showed no obvious external injuries. On internal examination, the heart revealed myocardial infarction, focal areas of fibrosis, and translucent *T. solium* cysts in the myocardium. The cause of death was myocardial infarction in a man with cardiac cysticercosis.

Case 4 was a 35-year-old male with no previous history of ill health who was found dead in his bed at home. There was no history or evidence of trauma, seizures, or poisoning. Internal examination revealed numerous *T. solium* cysts on the surface of the heart muscles, lateral ventricles of the brain, lung surfaces, and di-

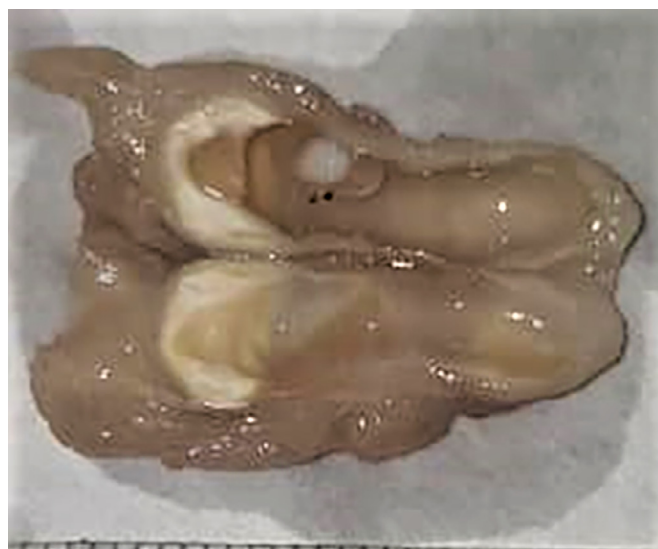

Figure 8. Gross appearance of a *Taenia solium* cyst.

aphragm. All of the other organs had no pathology. The cause of death was cardiac cysticercosis in a man with neurocysticercosis.

Case 5 was a 53-year-old male who died on the way to the hospital after complaining of severe headache and vomiting of less than 24 hours' duration. There was no history of alcohol abuse, seizures, or fever. The autopsy showed no external injuries. Internal examination showed numerous *T. solium* cysts in the heart muscles, brain leptomeninges, and ventricles. The cause of death was cardiac cysticercosis in a man with neurocysticercosis.

Case 6 was a 40-year-old male who complained of headache and vomiting and died soon after. There was no prior history of seizures, vomiting, or fever. The autopsy showed no external injuries. On internal examination, numerous *T. solium* cysts were seen on the surface and muscles of the heart, all ventricles of the brain, and omentum. The cause of death was attributed to cardiac cysticercosis in a man with neurocysticercosis.

Case 7 was a 51-year-old-male, known alcoholic, who was found dead in his car after a binge drinking episode. The autopsy showed no external injuries. Internal examination showed numerous *T. solium* cysts in the muscles of the heart, leptomeninges, and ventricles of the brain. The cause of death was acute alcohol intoxication in a man with cardiac cysticercosis and neurocysticercosis.

Case 8 was a 28-year-old-male, known alcoholic, who died unexpectedly at home. The autopsy examination showed no external injuries. On internal examination, translucent *T. solium* cysts were seen on the heart surface and heart muscles. The lungs showed left-sided bronchopneumonia. The autopsy causes of death were bronchopneumonia in a man with cardiac cysticercosis and chronic alcoholism.

Case 9 was a 55-year-old-male, known alcoholic, who fell ill at home with breathlessness and fever and died on the way to hospital. There was no history of seizures. The kidneys showed renal abscesses and pyelonephritis. The autopsy showed multiple *T. solium* cysts on the brain leptomeninges and ventricles. The cause of death was acute pyelonephritis in a man with neurocysticercosis.

4. Discussion

There are several notable findings from this study. Although cysticercosis is widespread globally (WHO, 2021; CDC, 2021; Dixon et al., 2020; Sorvillo and DeGiorgio, 2020; Sorvillo et al., 2011; Phiri et al., 2003; Schantz et al., 1988; Garcia and Del Brutto, 2005), autopsy data regarding sudden and unexpected community deaths due to cardiac cysticercosis are scarce. First, this appears to be the first and largest case series reporting nine cases of cysticercosis as an incidental finding at autopsy in sudden and unexpected deaths in the community subjected to forensic investigations. Second, eight out of nine cases had cardiac cysticercosis. Third, cardiac cysticercosis was a definitive cause of death in two cases and a contributing cause in others. Fourth, all nine decedents with cysticercosis seen at autopsy were not suspected of having cysticercosis prior to death and the diagnosis only became apparent on autopsy.

There have been very few reports of fatal cardiac cysticercosis reported globally (Spina et al., 2013; Eberly et al., 2008; Eberly et al., 2008). Cardiac cysticercosis is rarely diagnosed antemortem. *T. solium* cysts can be randomly distributed in cardiac tissue, and thus cardiac cysticercosis may remain subclinical, asymptomatic, or present with arrhythmias, cardiac symptoms, and rarely sudden death (Sorvillo and DeGiorgio, 2020; Hortobágyi et al., 2009). Case 3 shows that whilst people with cardiac cysticercosis can live asymptotically or remain undetected antemortem, stressful encounters could further compromise heart function leading to death. A case report has described cardiac cysticercosis as a rare cause of myocardial infarction (Nery et al., 2018).

Cases 1 and 4 showed a disseminated form of the disease. This is in keeping with previous studies that have shown that *T. solium* can be found in any organ of the body, hence explaining the associated high morbidity (Jain et al., 2010; Nery et al., 2018; Jain et al., 2010; Bhalla et al., 2008). The present study data show that it is important for the forensic pathologist to be aware of the possibility of cysticercosis when performing autopsies of sudden and unexpected deaths in the community.

Whilst cysticercosis is known to have a predilection for the brain (WHO, 2021; Schantz et al., 1988; Nash and Garcia, 2011; Wallin and Kurtzke, 2004; Garcia and Del Brutto, 2005) and is a leading cause of adult-onset seizures in developing countries (Dixon et al., 2020; Sorvillo and DeGiorgio, 2020), there have been only a few individual autopsy case reports of neurocysticercosis as a cause of sudden death (Esberg and Reske-Nielsen, 1988; Hortobágyi et al., 2009; Ndhlovu, 1997). One case involved a road traffic accident that resulted in previously undiagnosed neurocysticercosis causing cerebral complications (Holmes et al., 2010).

Six of the nine cases of cysticercosis reported here showed *T. solium* cysts in the brain. Sudden death in neurocysticercosis may be associated with a range of underlying or consequential pathological processes and intracranial location. The racemose form of neurocysticercosis is associated with mortality of up to 50% (Sorvillo and DeGiorgio, 2020). Cases 5 and 6 presented with a history of headache and vomiting, which may have resulted from raised intracranial pressure, due to disturbances in the flow of the cerebrospinal fluid caused by the cysts. Neurocysticercosis has been associated with increased intracranial pressure leading to seizure disorders, abnormal cognition, and mortality (Sorvillo and DeGiorgio, 2020; Nash and Garcia, 2011; Abanto et al., 2021).

All of the cysticercosis cases here were male and aged between 26 and 56 years. Most were alcoholics and lived in high population density and low socioeconomic communities. Six of the nine decedents were alcoholics. The study data need to be viewed with consideration of the limitations of the data reporting incidental cysticercosis cases found at forensic examination. Other contributing factors to death such as hypoglycemia and ketoacidotic states may have been covered in the contributory section statement of the cause of death statement, which highlighted alcoholism as having a cause effect association in these sudden deaths. Whilst alcoholism has not been described as a risk factor for cysticercosis, the cases presented here had frequently visited beer halls and bars where grilled pork is served. It is possible that the cysticercosis infections resulted from the consumption of contaminated undercooked infected pork in these cases. However, no follow-up public health contact tracing or epidemiological investigations took place, due to logistics, a lack of resources, and COVID-19 restrictions.

Another route of infection in the study cases may have been fecal–oral transmission, as a result of close contact and poor hygiene practices with individuals infected with adult *T. solium* tapeworms. These individuals are mostly asymptomatic and may not be cognizant of their infection or the potential risk to themselves (autoinfection) and others (Garcia and Del Brutto, 2005; WHO, 2021). *T. solium* causes two distinct conditions in humans, taeniasis and cysticercosis (Garcia and Del Brutto, 2005; WHO, 2021). Human taeniasis occurs when a person eats raw or undercooked pork infected with *T. solium* cysts, which once hatched into larvae, grow into an adult tapeworm in the human gut (Garcia and Del Brutto, 2005; WHO, 2021). The adult tapeworm then sheds proglottids containing ova into human feces, which contaminate the environment in the absence of proper sewage systems. Future studies where cysticercosis is found at autopsy should be associated with follow up epidemiological investigations in order to determine the source and prevalence of *T. solium* infections to guide intervention measures and stop transmission. A recent systematic review of the distribution of cysticercosis in West and Central Africa

(Bhalla et al., 2008) showed continuing public health issues with taeniosis and cysticercosis and that an overall One Health approach is needed to control tapeworm infection.

When taken in aggregate, the diagnosis of cysticercosis can be used by public health to map directed surveillance systems, implement public awareness programs for prevention, and treat sources in households and the community. This study showed that at autopsy, cardiac cysticercosis and neurocysticercosis are important underlying causes of death, or contributing causes of death. It also illustrated that forensic autopsies can provide useful information on the undiagnosed burden of locally prevalent infectious diseases, which may be incidental. Furthermore, they may contribute to help identify the presence of cysticercosis and other subclinical and undiagnosed causes of death in the public.

The exact prevalence of cysticercosis in most parts of the world remains unknown. The geographical overlap of Africa's burden of malaria, HIV, tuberculosis, COVID-19, and parasitic diseases, including cysticercosis, and the paucity of data on their contribution to deaths in the community (Jewell et al., 2021; Hendrickx et al., 2019) calls for more investment in autopsy services to conduct high quality research. Medico-legal forensic autopsy work could also provide an insight into disease clusters in the community, data that could be useful for public health surveillance, monitoring, and directed preventive measures.

Acknowledgements

We thank the mortuary staff for their assistance with performing the autopsies.

Sir Prof. Alimuddin Zumla, Professor Francine Ntoumi, Drs Mucheleng'anga Luchenga, Tembo John, and Kapata Nathan acknowledge support from the EU-EDCTP funded PANDORA-ID-NET, the Pan-African Network For Rapid Research, Response, Relief and Preparedness for Infectious Disease Epidemics, CANTAM-3 and EACCR-3, and NIHR-BRC. Sir Zumla is a Mahathir Foundation Science Award and Pascoal Mocumbi Prize laureate.

Declarations

Funding source: This research did not receive any specific grant from funding agencies in the public, commercial, or not-for-profit sectors.

Conflict of interest: All authors declare no conflicts of interest.

Author contributions

Cordilia Himwaze and Luchenga Mucheleng'anga performed the forensic autopsy investigations. Cordilia Himwaze, Luchenga Mucheleng'anga, and Alimuddin Zumla ideated the study. All authors contributed to intellectual discussions, data analyses, and manuscript writing.

REFERENCES

- Abanto J, Blanco D, Saavedra H, Gonzales I, Siu D, Pretell EJ, et al. Cysticercosis Working Group in Peru. Mortality in Parenchymal and Subarachnoid Neurocysticercosis. *Am J Trop Med Hyg* 2021;105(1):176–80 Jul 7.
- Bhalla A, Sood A, Sachdev A. Heart involvement in disseminated cysticercosis- a case report and review of literature. *Indian Heart J* 2008;60(3):260–2 May-Jun PMID:19240318 .
- CDC 2021. Parasites. Cysticercosis. <https://www.cdc.gov/parasites/cysticercosis/index.html> -accessed 2nd November, 2021
- Dixon MA, Winskill P, Harrison WE, et al. Force-of-infection of *Taenia solium* porcine cysticercosis: a modelling analysis to assess global incidence and prevalence trends. *Sci Rep* 2020 Oct 19;10(1):17637.
- Eberly MD, Soh EK, Bannister SP, Tava-Motamen H, Scott JS. Isolated cardiac cysticercosis in an adolescent. *Pediatr Infect Dis J* 2008;27(4):369–71 Apr PMID:18316979 . doi:10.1097/INF.0b013e318163d316.
- Esberg G, Reske-Nielsen E. Sudden death from cerebral cysticercosis. *Scand J Infect Dis* 1988;20(6):679–84 PMID:3222678 . doi:10.3109/00365548809035670.
- Garcia HH, Del Brutto OH, et al. Cysticercosis Working Group in Peru Neurocysticercosis: updated concepts about an old disease. *Lancet Neurol* 2005;4:653–61. doi:10.1016/S1474-4422(05)70194-0.
- Hendrickx E, Thomas LF, Dorny P, et al. Epidemiology of *Taenia saginata* taeniosis/cysticercosis: a systematic review of the distribution in West and Central Africa. *Parasit Vectors* 2019;12(1):324 Jun 27 PMID:31248445 PMID: PMC6598244. doi:10.1186/s13071-019-3584-7.
- Holmes NE, Iles LE, Danks RA, Korman TM. Neurocysticercosis causing sudden death. *Am J Forensic Med Pathol* 2010;31(2):117–19 Jun PMID:20139756 . doi:10.1097/PAF.0b013e3181cfc8a3.
- Hortobágyi T, Alhakim A, Biedrzycki O, Djurovic V, Rawal J, Al-Sarraj S. Cysticercosis of the fourth ventricle causing sudden death: a case report and review of the literature. *Pathol Oncol Res* 2009;15(1):143–6 Mar Epub 2008 Sep 18. PMID:18802793 . doi:10.1007/s12253-008-9098-9.
- Jain BK, Sankhe SS, Agrawal MD, Naphade PS. Disseminated cysticercosis with pulmonary and cardiac involvement. *Indian J Radiol Imaging* 2010;20(4):310–13. doi:10.4103/0971-3026.73532.
- Jewell PD, Abraham A, Schmidt V, et al. Neurocysticercosis and HIV/AIDS co-infection: A scoping review. *Trop Med Int Health* 2021;26(10):1140–52 Oct.
- Kalra DK, Rao A, Simms A, Pierre-Louis A. Isolated cardiac cysticercosis: treatment with or without steroids? *Lancet* 2019;393(10189):2439 Jun 15 PMID:31204684 . doi:10.1016/S0140-6736(19)31268-1.
- Mucheleng'anga LA, Telendiy V, Hamukale A, Shibemba AL, Zumla A, Himwaze CM. COVID-19 and Sudden Unexpected Community Deaths in Lusaka, Zambia, Africa - A Medico-Legal Whole-Body Autopsy Case Series. *Int J Infect Dis* 2021;109:160–7.
- Nash TE, Garcia HH. Diagnosis and treatment of neurocysticercosis. *Nat Rev Neurol* 2011;7(10):584–94 Published 2011 Sep 13. doi:10.1038/nrneurol.2011.135.
- Ndhlovu CE. An uncommon presentation of cysticercosis. *Cent Afr J Med* 1997;43(7):207–9 Jul PMID:9431756 .
- Nery TB, Gelape CL, Passaglia LG, Lopes do Carmo GA. Cardiac cysticercosis: A rare cause of myocardial infarction, Brazil. *J Thoracic Cardiovasc Surgery* 2018;155 5 e155-.
- Phiri IK, Ngowi H, Afonso S, Matenga E, Boa M, Mukaratirwa S, et al. The emergence of *Taenia solium* cysticercosis in eastern and southern Africa as a serious agricultural problem and public health risk. *Acta Trop* 2003;87:13–23.
- Schantz PM, Wilkins PP, Tsang VC. Immigrants, imaging, and immunoblots: the emergence of neurocysticercosis as a significant public health problem. In: Scheld WM, Craig WA, Hughes JM, editors. *Emerging infections*. Washington: ASM Press; 1998. p. 213–42.
- Sorvillo F, Wilkins P, Shafir S, Eberhard M. Public health implications of cysticercosis acquired in the United States. *Emerg Infect Dis* 2011;17(1):1–6.
- Spina R, Sandaradura I, Puranik R, Lee AS. Cardiac cysticercosis. *Int J Cardiol* 2013 Sep 20;168(1):557–9 Epub 2013 Mar 5. PMID:23465559 . doi:10.1016/j.ijcard.2013.01.183.
- Wallin MT, Kurtzke JF. Neurocysticercosis in the United States: review of an important emerging infection. *Neurology* 2004;63:1559–64.
- WHO. Taeniasis/cysticercosis <https://www.who.int/news-room/fact-sheets/detail/taeniasis-cysticercosis> -accessed 1st November 2021.